

## ***Senecio brasiliensis* (Asteraceae) poisoning in Murrah buffaloes in Rio Grande do Sul<sup>1</sup>**

André M.R. Corrêa<sup>2</sup>, Pedro S. Bezerra Junior<sup>2</sup>, Saulo P. Pavarini<sup>2</sup>, Adriana S. Santos<sup>2</sup>, Luciana Sonne<sup>2</sup>, Priscila Zlotowski<sup>2</sup>, Gisele Gomes<sup>3</sup> and David Driemeier<sup>2\*</sup>

**ABSTRACT.-** Corrêa A.M.R., Bezerra P.S.J., Pavarini S.P., Santos A.S., Sonne L., Zlotowski P., Gomes G. & Driemeier D. 2008. ***Senecio brasiliensis* (Asteraceae) poisoning in Murrah buffaloes in Rio Grande do Sul.** *Pesquisa Veterinária Brasileira* 28(3):187-189. Departamento de Patologia Clínica Veterinária, Universidade Federal do Rio Grande do Sul, Av. Bento Gonçalves 9090, Porto Alegre, RS 91540-000, Brazil. E-mail: [davetpat@ufrgs.br](mailto:davetpat@ufrgs.br)

Thirteen (14.4%) out of 90 Murrah buffaloes (*Bubalus bubalis*) became ill after consumption of *Senecio brasiliensis*, and 11 (12.2%) of them died. The buffaloes were kept in a highly *Senecio brasiliensis* infested area. The poisoning occurred in June-August 2006 on a farm in the county of Nova Prata, Rio Grande do Sul, southern Brazil. Clinical signs included weakness, apathy, progressive weight loss, permanent decubitus, and diarrhea. Necropsy was performed in 2 of the 11 buffaloes that died. The pathological findings were typical of poisoning by pyrrolizidine alkaloids. High infestation of pastures with *S. brasiliensis*, severe drought, and consequent starvation were the main epidemiological factors associated with the poisoning here described.

INDEX TERMS: Buffaloes, pyrrolizidine alkaloids, *Senecio* poisoning.

### **RESUMO.- [Intoxicação natural por *Senecio brasiliensis* (Asteraceae) em bubalinos no Rio Grande do Sul.]**

Descreve-se a ocorrência de um surto de intoxicação espontânea por *Senecio brasiliensis* em búfalos Murrah (*Bubalus bubalis*) em uma propriedade localizada no município de Nova Prata, Estado do Rio Grande do Sul, no período de junho a agosto de 2006. De um total de 90 búfalos, 13 adoeceram e 11 morreram. Os animais eram mantidos em áreas de pastoreio altamente infestadas por *S. brasiliensis*. Os principais sinais clínicos relatados foram letargia, apatia, emagrecimento progressivo, diarréia e decúbito permanente. Necropsia foi feita em dois dos 11 animais mortos. As lesões foram características de

intoxicações por alcalóides pirrolizidínicos. A grande quantidade da planta, forte estiagem e desnutrição conseqüente foram os principais achados epidemiológicos associados com a mortalidade.

TERMOS DE INDEXAÇÃO: Alcalóides pirrolizidínicos, búfalos, intoxicação por *Senecio*.

### **INTRODUCTION**

There are about 128 species of the genus *Senecio* in Brazil. Although a number of these species occur in Rio Grande do Sul, only *Senecio brasiliensis*, *S. oxyphyllus*, *S. heterotrichus*, and *S. selloi* have frequently been associated with poisoning in animals, of which cattle (Driemeier et al. 1991, Barros et al. 1992, Driemeier & Barros 1992) horses (Gava & Barros 1997) and sheep (Ilha et al. 2001) may be affected. *Senecio brasiliensis*, also known as maria-mole, berneira, flor-de-outubro, tasneirinha, and flor-das-almas, is the most widely occurring species of the genus in southern Brazil (Motidome & Ferreira 1966).

The toxic compounds of *Senecio* spp. include a group of potent hepatotoxins named pyrrolizidine alkaloids (Bull et al. 1968). About 50% of all deaths caused by toxic plants

<sup>1</sup> Recebido em 14 de novembro de 2007.

Aceito para publicação em 11 de dezembro de 2007.

<sup>2</sup> Setor de Patologia Veterinária (SPV), Departamento de Patologia Clínica Veterinária, Faculdade de Veterinária, Universidade Federal do Rio Grande do Sul (UFRGS), Av. Bento Gonçalves 9090, Porto Alegre, RS 91540-000, Brazil. E-mail: [davetpat@ufrgs.br](mailto:davetpat@ufrgs.br)

<sup>3</sup> Inspetoria Veterinária de Nova Prata, Secretaria de Agricultura e Abastecimento do Rio Grande do Sul, Av. Borges de Medeiros 1173, 2º andar, Nova Prata, RS 95320-000, Brazil.

in cattle in southern Brazil and Uruguay are due to the consumption of *Senecio* spp., which therefore cause large economic losses for farms and ranches in the region (Riet-Correa & Medeiros 2001, Schild et al. 2004).

Murrah buffaloes were introduced into Brazil at the end of the last century, initially into the Marajó Island, state of Pará. However, its importance to meat and milk producers has only lately been recognized in this country. The buffalo herd has experienced a significant, steady and uniformly distributed increase in all Brazilian regions. No other reports of *Senecio* poisoning in Murrah buffaloes have been found.

## MATERIALS AND METHODS

Clinical signs and epidemiological data were retrieved from the herd's owner and the local veterinarian. Fragments of tissues were collected at necropsy from a 2-year-old Murrah buffalo cow, formalin-fixed and submitted to our Laboratory (SPV, UFRGS) by the local veterinarian for diagnostic purposes. After an initial suspicion of *Senecio* poisoning, a second necropsy was performed during a farm visit by our personnel in an 1-year-old male Murrah buffalo, which was euthanized with barbiturates due to an untreatable terminal state. Blood samples were collected for determination of serum levels of hepatic enzymes. Tissue fragments were fixed in 10% formalin, routinely processed for histology, and stained with hematoxylin and eosin (HE); in addition, Masson's trichrome staining was performed in selected liver sections (Prophet et al. 1992).

## RESULTS

The disease occurred from June to August 2006 on a farm located in the county of Nova Prata, Rio Grande do Sul, Brazil. Thirteen out of 90 buffaloes were affected, and 11 of them died. The other two apparently recovered after a prolonged illness. During the summer months of 2006, the farmer kept the buffaloes grazing on a 110 ha paddock in which large amounts of "caraguatá" (*Eryngium pandanifolium*), "maria-mole" (*Senecio brasiliensis*), and some others invader plants were established. The farmer expressed his hope that buffaloes could help to control such weeds. After summer, buffaloes would be transferred to another paddock, and cattle would then be turned to this area and kept there during autumn and winter. In summer 2006, when a long lasting drought occurred, the buffaloes were maintained longer than usually in the weed infested paddock, the only area on the farm where some green forage could yet be found. In the previous summer, this paddock had been grazed simultaneously by sheep and cattle. The owner noticed that after the months of drought, *Senecio brasiliensis* grew more intensively than other invader plants present in that field.

Affected buffaloes showed weakness, apathy, progressive weight loss, permanent decubitus, and diarrhea. At necropsy, main gross findings were ascites, edema of the mesentery, abomasum, omasum, and the intestines, as well as endocardic hemorrhages. The liver was pale, with diminished size and enhanced consistency. The gallbladder

had increased size and a thickened and edematous wall. Microscopic findings included cellular disorganization of the hepatic parenchyma with megalocytosis, vacuolation, diffuse and moderated fibrosis especially evident in the portal region, cholestasis, and bile duct proliferation. Hepatocytes showed irregular intranuclear pseudo-inclusion bodies and vacuolated nuclei. Fibrosis and occlusion of centrolobular veins, micronodular regeneration of hepatocytes, and individual necrosis of hepatocytes were also significant findings, easily observed with Masson's trichrome staining (Fig.1). Vacuolation at the junction of the cerebral gray matter and subcortical white matter of the central nervous system (Fig.2), vacuolation and fragmentation of myofibers in the diaphragm, and splenic hemosiderosis was also seen.

Biochemical analysis revealed significant increase in total bilirubin (1.22mg/dL), AST (328.7mg/dL), and ALT (53.4mg/dL) levels.




Fig.1. Disorganization of the hepatic parenchyma and fibrosis with micronodular regeneration of hepatocytes, individual necrosis and bile duct proliferation, in a buffalo poisoned by *Senecio brasiliensis*. Masson's trichrome staining, obj. 20x.

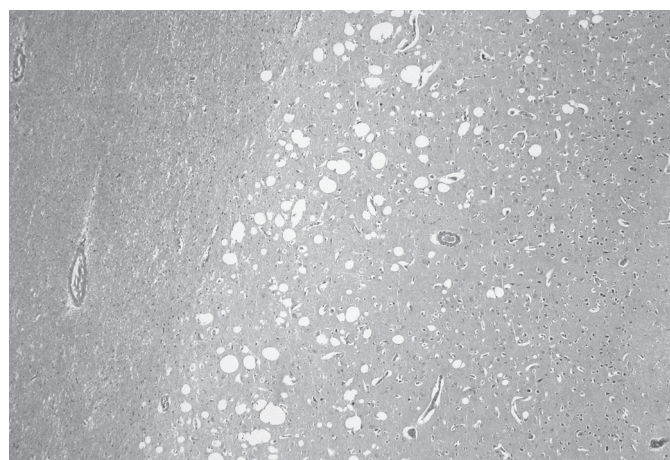


Fig.2. Vacuolation at the junction of the cerebral gray matter and subcortical white matter at the level of frontal lobe of the brain in a buffalo poisoned by *Senecio brasiliensis*. HE, obj. 10x.

## DISCUSSION

In the past years an increased number of *Senecio* poisoning outbreaks has been preceded by severe drought and high infestation of the grazing fields by *Senecio* sp. (Driemeier et al. 1991). Factors such as excessive cold with frost, drought, and overgrazing could influence the evolution of the local vegetation (Gonçalves & Girardi-Deiro 1986, Gonçalves et al. 1988), and therefore may have induced the establishment of unwanted plants like *Eryngium pandanifolium* and *Senecio brasiliensis* in the area.

Although sheep have been suggested to control the vegetative growth of *Senecio* species due to their lower susceptibility to pyrrolizidine alkaloids (Tokarnia et al. 2000), these animals may have also acted as seed dispersers for *Senecio brasiliensis* (Harper & Wood 1957, Karam et al. 2004), because sheep grazed the same infested paddock in the previous summer.

The clinical, pathological, and biochemical findings were consistent with previous reports of *Senecio* poisoning in cattle (Barros et al. 1987, Méndez et al. 1987, Tokarnia et al. 2000). Spongy degeneration of the white matter is a consistent finding in ruminants with hepatic encephalopathy, and has been associated with pyrrolizidine alkaloid poisoning (Tokarnia et al. 2000). Such lesions could have caused intense neurological signs, but which were not noticed. The lack of clinical data may be linked to infrequent observations of the animals at pasture or neurological signs may not be typical in buffaloes.

Buffaloes are animals characterized by a high degree of rusticity, which may be the reason for the low number of plant poisoning reports for the species, compared to cattle. Although there is no information about the sensibility of the species to pyrrolizidine alkaloids, buffaloes have been shown as more resistant than cattle to some toxic plants (Barbosa et al. 2003, Tokarnia et al. 2004). Probably, poor management practices such as to keep starving animals in a *Senecio brasiliensis* infested area have contributed to the occurrence of these cases. This report highlights the significant economic losses associated with the management of buffaloes in *Senecio brasiliensis*-infested pastures.

## REFERENCES

- Barbosa J.D., Oliveira C.M.C., Tokarnia C.H. & Riet-Correa F. 2003. Comparação da sensibilidade de bovinos e búfalos à intoxicação por *Palicourea marcgravii* (Rubiaceae). *Pesq. Vet. Bras.* 23(4):167-172.
- Barros C.S.L., Metzendorf L.L. & Peixoto P.V. 1987. Ocorrência de surtos de intoxicação por *Senecio* spp. (Compositae) em bovinos no Rio Grande do Sul. *Pesq. Vet. Bras.* 7(4):101-107.
- Barros C.S., Driemeier D., Pilati C., Barros S.S. & Castilhos L.M.L. 1992. *Senecio* spp. poisoning in cattle in southern Brazil. *Vet. Hum. Toxicol.* 34(3):241-246.
- Bull L.B., Culvenor C.C.T. & Dick A.T. 1968. The pyrrolizidine alkaloids. Their chemistry, pathogenicity and other biological properties. North-Holland Publ., Amsterdam, p.293.
- Driemeier D., Barros C.S.L. & Pilati C. 1991. Seneciose em bovinos. *Hora Vet., Porto Alegre*, 59:23-30.
- Driemeier D. & Barros C.S.L. 1992. Intoxicação experimental por *Senecio oxyphyllus* (Compositae) em bovinos. *Pesq. Vet. Bras.* 12(1/2):33-42.
- Gava A. & Barros C.S.L. 1997. *Senecio* spp. poisoning of horses in southern Brazil. *Pesq. Vet. Bras.* 17(1):36-40.
- Gonçalves J.O.N. & Girardi-Deiro A.M. 1986. Efeito de três cargas animais sobre a vegetação de pastagem natural. *Pesq. Agropec. Bras.* 21(5):547-554.
- Gonçalves J.O.N., Girardi-Deiro A.M. & Gonzaga S.S. 1988. Campos naturais ocorrentes nos diferentes tipos de solos no município de Bagé, RS. 1. Caracterização, localização e principais componentes da vegetação. *Bolm Pesq.* 12, Embrapa, Bagé, RS. 28p.
- Harper J.L. & Wood W.A. 1957. Biological flora of the British Isles: *Senecio jacobaea* L. *J. Ecology* 45:617-637.
- Ilha M.R.S., Loretto A.P., Barros S.S. & Barros C.S.L. 2001. Intoxicação espontânea por *Senecio brasiliensis* (Asteraceae) em ovinos no Rio Grande do Sul. *Pesq. Vet. Bras.* 21(3):123-138.
- Karam F.S.C., Soares M.P., Haraguchi M., Riet-Correa F., Méndez M.C. & Jarenkow J.A. 2004. Aspectos epidemiológicos da seneciose na região sul do Rio Grande do Sul. *Pesq. Vet. Bras.* 24(4):191-198.
- Méndez M.C., Riet-Correa F., Schild A.L. & Martz W. 1987. Intoxicação por *Senecio* spp. (Compositae) em bovinos no Rio Grande do Sul. *Pesq. Vet. Bras.* 7(2):51-56.
- Motidome M. & Ferreira P.C. 1966. Alcalóides do *Senecio brasiliensis* Less. *Revta Fac. Farmácia e Bioquímica USP* 4:38-44.
- Prophet E.B., Mills B., Arrington J.B. & Sobin L.H. 1992. Laboratory Methods in Histotechnology. Armed Forces Institute of Pathology, Washington, DC. 279p.
- Riet-Correa F. & Medeiros R.M.T. 2001. Intoxicações por plantas no Brasil e no Uruguai: importância econômica, controle e riscos para a saúde pública. *Pesq. Vet. Bras.* 21(1):38-42.
- Schild A.L., Motta A.C., Riet-Correa F., Karam F.C. & Grecco F.B. 2004. Photosensitivity in cattle in southern Brazil, p.162-166. In: Acamovic T., Stewart C.S. & Pennycott T.W. (ed.), *Poisoning Plants and Related Toxins*. CAB International, London.
- Tokarnia C.H., Döbereiner J. & Peixoto P.V. 2000. Plantas Tóxicas do Brasil. Editora Helianthus, Rio de Janeiro. 310p.
- Tokarnia C.H., Barbosa J.D., Oliveira C.M., Brito M.F. Oliveira R.B. & Barbas L.A. 2004. Aspectos epidemiológicos e clínico-patológicos comparados da intoxicação por *Arrabidaea bilabiata* em búfalos e bovinos. *Pesq. Vet. Bras.* 24(2):74-79.