

SHORT COMMUNICATION

First report of the nematode *Physaloptera praeputialis* parasitizing a jaguarandi

Primeiro registro do nematoide *Physaloptera praeputialis* parasitando puma

Rosiléia Marinho de Quadros¹
rosileia18@hotmail.com

Sandra Márcia Tietz Marques^{2*}
smtmuni@hotmail.com

Anderson Barbosa de Moura¹
anderson.moura@udesc.br

Marzia Antonelli¹
mahantonelli@hotmail.com

Abstract

Physaloptera praeputialis is a ubiquitous nematode with an indirect life cycle which has orthopterans and coleopterans as intermediate hosts, and amphibians, reptiles, birds, and mammals as definitive hosts. Its adult forms feed on blood and colonize the esophagus, the gastric mucosa, and the small intestine. Although the existence of records at others wild carnivores, this is the first report of *P. praeputialis* in *Puma yagouaroundi*, which was picked up dead from a roadkill in Passo dos Fernandes, between Lages and São José do Cerrito, in the highland region of southern Brazil.

Keywords: Spirurida, parasitic helminths, feline, digestive tract, Brazil.

Resumo

Physaloptera praeputialis é um nematoide cosmopolita com ciclo de vida indireto, cujos hospedeiros intermediários são ortópteros e coleópteros, e cujos hospedeiros definitivos são anfíbios, répteis, pássaros e mamíferos. Os parasitos adultos são hematófagos e vivem no esôfago, na mucosa estomacal e no intestino delgado. Embora existam registros em outros carnívoros selvagens, este relato documenta a primeira ocorrência de *P. praeputialis* parasitando *Puma yagouaroundi*, o qual foi resgatado sem vida em Passo dos Fernandes, entre Lages e São José do Cerrito, na região serrana do estado de Santa Catarina, Brasil.

Palavras-chave: Spirurida, helmintos parasitos, felino, tubo digestivo, Brasil.

Species of *Physaloptera* are parasitic nematodes belonging to the order Spirurida and family Physalopteridae. Their adult stages live in the digestive tract of amphibians (three species), reptiles (45 species), birds (24 species) and mammals (over 90 species), and there are more than 82 cases described in humans (Mohamadain and Ammar, 2012). Its life cycle includes intermediate hosts (orthopterans and coleopterans) or paratenic hosts that harbor larval forms in the outer intestinal wall (Figure 1). Domestic and wild carnivores (cougar, lynx, badger, raccoon, fox, striped hog-nosed skunk, coyote) may be infected after eating food contaminated with the parasite. The development into the adult form takes place

¹ Centro de Ciências Agroveterinárias. Universidade do Estado de Santa Catarina. Av. Luiz de Camões, 2090, Conta Dinheiro, 88520-000, Lages, SC, Brasil.

² Faculdade de Veterinária da Universidade Federal do Rio Grande do Sul. Av. Bento Gonçalves, 9090, Agronomia, 91540-000, Porto Alegre, RS, Brasil.

*Corresponding author

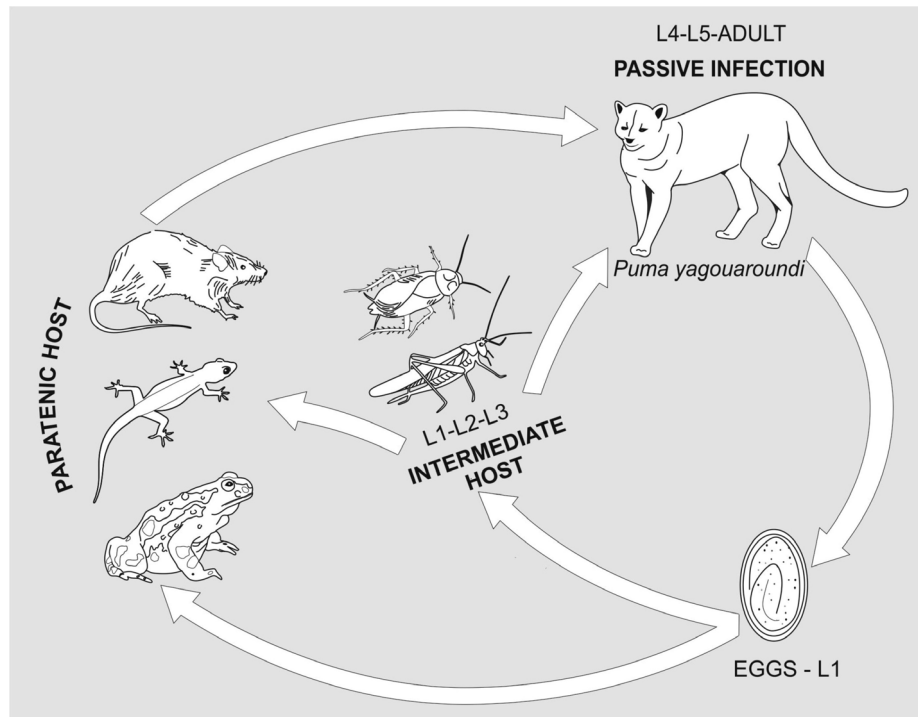


Figure 1. Life cycle of *Physaloptera praeputialis*.

in the definitive host and the worms lodge, preferably, in the esophagus, in the gastric mucosa, and in the small intestine (Schitoskey and Linder, 1981). These parasites are hematophagous and, after attaching to the gastric mucosa, they may erode it, leading to congestion, edema, and ulcers (Naem and Asadi, 2013). Gastric erosion results from the parasite's action, provoking local inflammatory reaction, causing catarrhal or hemorrhagic gastritis and anemia (Naem *et al.*, 2006).

One adult (about 3 year-old) female jaguarundi, *Puma yagouarundi* (E. Geoffroy, 1883) (Carnivora, Felidae), weighing 6.5 kg was picked up dead from a roadkill in Passo dos Fernandes (27°42'5.82"S and 50°32'25.56"W), between Lages and São José do Cerreto, in the mountain region of the state of Santa Catarina, Brazil (Figure 2). The animal was sent to the Laboratory of Parasitology of the Universidade do Planalto Catarinense (UNIPLAC) for necropsy and analysis of parasitic fauna. At necropsy, the stomach revealed partially digested

food remnants, including the paws of a common agouti (*Dasyprocta aguti* Linnaeus, 1766) and a grossly visible parasite identified as *Physaloptera praeputialis* (Figure 3), with the following characteristics: 3.2 cm in length, anterior region with triangular lips bearing small teeth, and cuticular sheath reflected forward at the anterior end to form a prepuce-like collar (Naem *et al.*, 2006). The small and large intestines did not have any helminths. A faecal sample was collected and examined by spontaneous sedimentation, revealing some embryonated eggs of *P. praeputialis* (59 x 31 µm) under light microscopy (Figure 4). This is the first report of *P. praeputialis* in a jaguarundi. In Brazil, there are reports of this parasite in domestic carnivores in Rio de Janeiro (Labarthe *et al.*, 2004), Minas Gerais (Mundim *et al.*, 2004) and São Paulo (Bresciani *et al.*, 2008), as well as in wild carnivores, i.e. the crab-eating fox, *Cerdocyon thous*, and the maned wolf, *Chrysocyon brachyurus*, in Minas Gerais (Santos *et al.*, 2012). In

other wild carnivores, it has been diagnosed in *Panthera leo* in Tanzania and Zimbabwe, respectively (Bjork *et al.*, 2000; Mukarati *et al.*, 2013) and *P. tigris* in India (Mahali *et al.*, 2010), in *Lynx* spp. in the United States and Spain (Schitoskey and Linder, 1981; Torres *et al.*, 1998), in *Puma concolor* in Mexico (Guerrero *et al.*, 2010) and in *Felis silvestris* in Spain (Rodríguez and Carbonell, 1998).

In Brazil, the wild felines are threatened by constant changes in ecosystems, deforestation, urbanization and construction of highways, altering ecological niches and increasing roadkills (Santos *et al.*, 2012; Clevenger *et al.*, 2003). For being at the top of the food chain, felines can put a curb on the population of natural preys and influence the whole ecosystem dynamics (Pitman *et al.*, 2002). *Puma yagouarundi* is widely distributed in North and South America (Oliveira, 1998), but studies have focused on the ecology of the species, on its eating habits and on population estimates (Bianchi *et al.*, 2011). Therefore, the present study plays an important role,

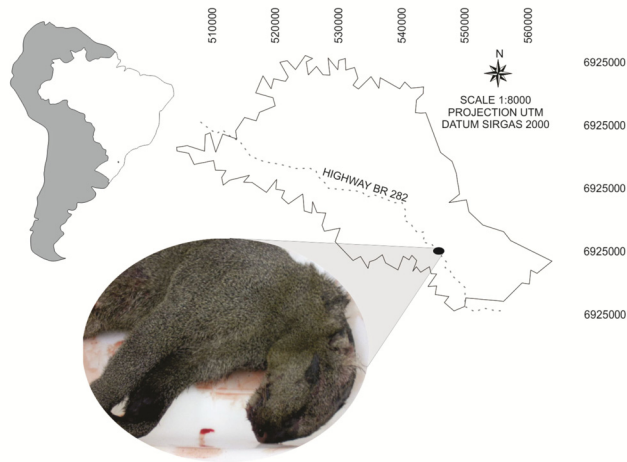

Figure 2. Sampling location of a parasitized specimen of *Puma yagouarundi*.

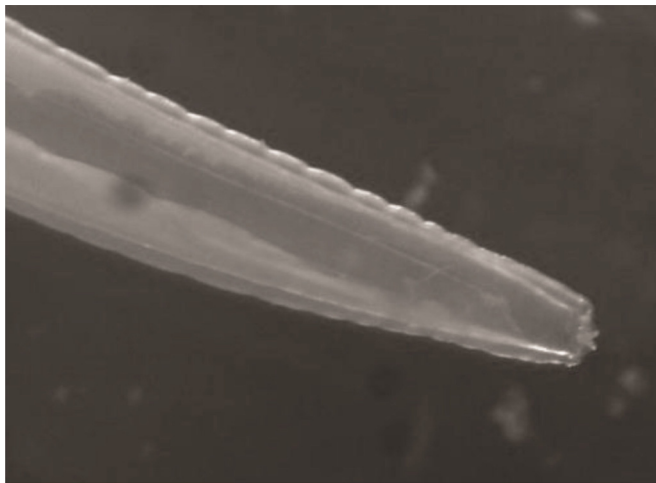


Figure 3. Anterior end of an adult female of *Physaloptera praeputialis* recorded in a jaguarundi (10 X).

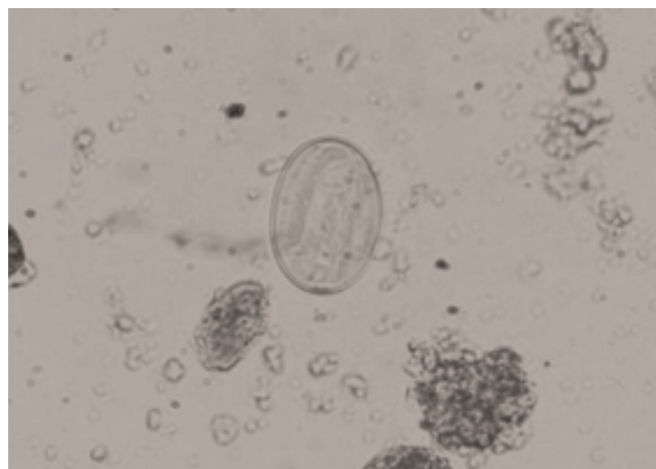


Figure 4. An egg of *Physaloptera praeputialis* in faeces of *Puma yagouarundi* (100X).

given the lack of data on *Physaloptera praeputialis* in wild felines, by expanding the reports of occurrence and describing, for the first time, an infection in *Puma yagouarundi*.

Despite the easy identification of *P. praeputialis* in definitive hosts, the infection is difficult to control, due to the variety of species that may serve as intermediate hosts. In the case of domestic animals, control is based on the elimination of intermediate and paratenic hosts, proper management of excreta, and appropriate treatment. Therefore, there is no report confirming the death of domesticated animals by this parasite, but a death due to this infection was reported in *Panthera tigris* at a British zoo. In this case the whole alimentary tract was in a condition of advanced catarrhal inflammation, with extensive chronic irritation of the gastric wall and large numbers of worms in the gastric lumen. During the development of the parasites, a fibrous nodule was formed, and the nodule extended into the muscle layer of the stomach causing considerable atrophy of the muscle fibres (Harrison and Hall, 1909). In wild animals, there are many limitations to conduct studies on parasitism, such as the study of specimens in their habitat and difficulties in capturing live animals for investigation, as well as in identifying the source of infection and susceptible species.

Acknowledgments

We are greatly indebted to Wilian Rafael Veronezi, technician at the Brazilian Environmental Institute - IBAMA for picking up and entrusting us the dead animal for investigation.

References

- BIANCHI, R.D.; ROSA, A.F.; GATTI, A.; MENDES, S.L. 2011. Diet of margay, *Leopardus wiedii*, *Puma yagouarundi* (Carnivora: Felidae), in Atlantic Rainforest, Brazil. *Zoologia*, **28**(1):127-132.
<http://dx.doi.org/10.1590/S1984-46702011000100018>
 BJORK, K.E.; AVERBECK, G.A.; STROMBERG, B.E. 2000. Parasites and parasite stages

- of free-ranging wild lions (*Panthera leo*) of northern Tanzania. *Journal of Zoo Wildlife Medicine*, **31**(1):56-61.
[http://dx.doi.org/10.1638/1042-7260\(2000\)031\[0056:PAPSO\]2.0.CO;2](http://dx.doi.org/10.1638/1042-7260(2000)031[0056:PAPSO]2.0.CO;2)
- BRESCIANI, K.D.S.; ISHIZAKI, M.N.; KANETO, C.N.; MONTANO, T.R.P.; PERRI, S.H.V.; VASCONCELOS, R.O.; NASCIMENTO, A.A. 2008. Frequência e intensidade parasitária de helmintos gastrintestinais em cães na área urbana do Município de Araçatuba, SP. *ARS Veterinária*, **24**(3):181-185. Available at: <http://www.arsveterinaria.org.br/index.php/ars/article/viewFile/197/160> Accessed on: 06/22/2014.
- CLEVENGER, A.P.; CHRUSZCZ, B.; GUNSON, K. 2003. Spatial patterns and factors influencing small vertebrate fauna road-kill aggregations. *Biological Conservation*, **109**:15-26.
[http://dx.doi.org/10.1016/S0006-3207\(02\)00127-1](http://dx.doi.org/10.1016/S0006-3207(02)00127-1)
- GUERRERO, J.H.M.; SOLIS, M.E.P.; RAMOS, J.J.Z.; ALFEREZ, F.R.; CASIO, H.H. 2010. Report of *Physaloptera praeputialis* (Von Linstow) in mountain lion (*Puma concolor*, Linnaeus, 1771). *Journal of Animal and Veterinary Advances*, **9**(3):601-603.
<http://dx.doi.org/10.3923/javaa.2010.601.603>
- HARRISON, A.J.; HALL, W. 1909. Fatal enteritis in a tiger caused by *Physaloptera praeputialis*. *Parasitology*, **2**(1-2):29-31.
<http://dx.doi.org/10.1017/S0031182000001530>
- LABARTHE, N.; SERRÃO, M.L.; FERREIRA, A.M.R.; ALMEIDA, N.K.O.; GUERRERO, J. 2004. A survey of gastrointestinal helminths in cats of the metropolitan region of Rio de Janeiro, Brazil. *Veterinary Parasitology*, **123**(1):133-139.
<http://dx.doi.org/10.1016/j.vetpar.2004.06.002>
- MAHALI, A.K.; PANDA, D.N.; PANDA, M.R.; MOHANTY, B.N.; SAHOO, N. 2010. Incidence and seasonal variation of gastrointestinal parasitic infections in captive carnivores in Nandankanan zoological park Orissa. *Journal of Veterinary Parasitology*, **24**(2):111-115. Available at: <http://www.indianjournals.com/ijor.aspx?target=ijor:jvp&volume=24&issue=2&article=002> Accessed on: 06/22/2014.
- MOHAMADAIN, H.S.; AMMAR, K.N. 2012. Redescription of *Physaloptera praeputialis* von Linstow, 1889 (Nematoda: Spirurida) infecting stray cats (*Felis catus* Linnaeus, 1758) in Qena, Egypt and overview of the genus taxonomy. *Journal of the Egyptian Society of Parasitology*, **42**(3):675-690.
- MUKARATI, N.L.; VASSILEV, G.D.; TAGWIREYI, W.M.; TAVENGWA, M. 2013. Occurrence, prevalence and intensity of internal parasite infections of African lions (*Panthera leo*) in enclosures at a recreation park in Zimbabwe. *Journal of Zoo and Wildlife Medicine*, **44**(3):686-693.
<http://dx.doi.org/10.1638/2012-0273R.1>
- MUNDIM, T.C.D.; OLIVEIRA JÚNIOR, S.D.; RODRIGUES, D.C.; CURY, M.C. 2004. Frequência de helmintos em gatos de Uberlândia, Minas Gerais. *Arquivo Brasileiro de Medicina Veterinária e Zootecnia*, **56**(4):562-563.
<http://dx.doi.org/10.1590/S0102-09352004000400022>
- NAEM, S.; FARSHID, A.A.; MARAND, V.T. 2006. Pathological findings on natural infection with *Physaloptera praeputialis* in cats. *Journal of Egyptian Society of Parasitology*, **76**(4):315-321.
- NAEM, S.; ASADI, R. 2013. Ultrastructural characterization of male and female *Physaloptera rara* (Spirurida: Physalopteridae): feline stomach worms. *Parasitology Research*, **112**(5):1983-1990.
<http://dx.doi.org/10.1007/s00436-013-3356-9>
- OLIVEIRA, T.G. 1998. *Herpailurus yagouaroundi*. Mammalian Species. *American Society of Mammalogists*, **578**:1-6.
<http://dx.doi.org/10.2307/3504500>
- PITMAN, M.R.PL.; OLIVEIRA, T.G.; PAULA, R.C.; INDRUSIAK, C. 2002. *Manual de identificação, prevenção e controle de predação por carnívoros*. Brasília, IBAMA, 83 p.
- RODRIGUEZ, A.; CARBONELL, E. 1998. Gastrointestinal parasites of the Iberian lynx and other wild carnivores from central Spain. *Acta Parasitologica*, **43**(3):128-136.
- SANTOS, A.L.P.G.; ROSA, C.A.; BAGER, A. 2012. Variação sazonal da fauna selvagem atropelada na rodovia MG 354, Sul de Minas Gerais – Brasil. *Biotemas*, **25**(1):73-79.
<http://dx.doi.org/10.5007/2175-7925.2012v25n1p73>
- SCHITOSKEY, E.; LINDER, R. 1981. Helminths of Dakota bobcats. *Proceedings of South Dakota Academic Science*, **60**:135-141.
- TORRES, J.; GARCÍA-PÉREA, R.; GISBERT, J.; FELIU, C. 1998. Helminth fauna of the Iberian lynx, *Lynx pardinus*. *Journal of Helminthology*, **72**(3):221-226.
<http://dx.doi.org/10.1017/S0022149X00016473>

Submitted on June 11, 2014
 Accepted on September 24, 2014