



Evaluation of troponin I and C in horses intoxicated by salinomycin

Camila B. Pohl^{1*}, Bianca S. Cecco², Luan C. Henker², Marcele B. Bandinelli²,
Ronaldo M. Bianchi², Welden Panziera², Saulo P. Pavarini²
and David Driemeier²

ABSTRACT. Pohl C.B., Cecco B.S., Henker L.C., Bandinelli M.B., Bianchi R.M., Panziera W., Pavarini S.P. & Driemeier D. 2023. **Evaluation of troponin I and C in horses intoxicated by salinomycin.** *Pesquisa Veterinária Brasileira* 43:e07261, 2023. Setor de Patologia Veterinária, Departamento de Patologia Clínica Veterinária, Faculdade de Veterinária, Universidade Federal do Rio Grande do Sul, Av. Bento Gonçalves 9090, Prédio 42505, Porto Alegre, RS 91540-000, Brazil. E-mail: cacabpohl@gmail.com

Ionophores are antibiotics frequently used in animals of production. The most common are monensin, salinomycin, narasin, and lasalocid. The equine species is highly susceptible to ionophores poisoning. The present study aimed to analyze the serum use of cardiac troponin I (cTnI) and the anti-troponin C immunohistochemistry (IHC) technique (anti-cTnC) as a diagnostic tool for cardiac injuries in horses spontaneously poisoned by salinomycin. Seven horses were affected by a disease lasting for 6-72 hours. Three horses recovered. The primary morphological lesions reported in the four necropsied horses that died spontaneously were necrosis of the myocardium and skeletal muscle. Immunohistochemistry for anti-cTnC was performed in selected sections of the cardiac muscle from the equine submitted for necropsy. A decrease in cTnC expression in the cytoplasm of cardiomyocytes was noticed in all four necropsied horses. Samples of serum from six horses tested for cardiac troponin I levels; the most expressive values were mainly in horses with more severe cardiac histological lesions. The serum detection of cTnI can be considered a good marker to determine cardiac damage in horses intoxicated with salinomycin with a clinical evolution of 48 hours or more. The anti-cTnC IHC aided in the detection of cardiac injury in horses independent of clinical evolution.

INDEX TERMS: Equine diseases, salinomycin, toxic cardiomyopathy, immunohistochemistry, serum troponin, horses.

RESUMO. [Avaliação da troponina I e C em equinos intoxicados por salinomicina.] Ionóforos são antibióticos frequentemente utilizados em animais de produção. Dentre eles, os mais comuns são a monensina, salinomicina, narasina e lasalocida. A espécie equina é altamente suscetível à intoxicação por antibióticos ionóforos. O objetivo do presente estudo foi analisar o uso da troponina sérica cardíaca I (cTnI) e da técnica de imuno-histoquímica anti-troponina C (IHC) (anti-cTnC), como ferramenta diagnóstica para lesões cardíacas em equinos intoxicados espontaneamente por salinomicina. Sete equinos foram afetados, com evolução clínica de seis a 72 horas.

Destes, quatro foram necropsiados e três se recuperaram. As principais lesões morfológicas observadas foram necrose do miocárdio e dos músculos esqueléticos. A imuno-histoquímica anti-cTnC foi realizada em amostras selecionadas de tecido cardíaco dos quatro equinos submetidos à necropsia. Em todos os casos foi observada diminuição da expressão de cTnC no citoplasma dos cardiomiócitos. Amostras de soro de seis equinos foram submetidas à dosagem de troponina cardíaca I. Os valores mais altos foram observados em equinos que apresentaram lesões histológicas cardíacas mais graves. A detecção sérica de cTnI pode ser considerada um bom marcador para determinar lesão cardíaca em equinos intoxicados com salinomicina com evolução clínica de 48 horas ou mais. A IHC anti-cTnC auxiliou na detecção da lesão cardíaca nos equinos independente da evolução clínica.

TERMOS DE INDEXAÇÃO: Doença de equinos, salinomicina, cardiomiopatia tóxica, imuno-histoquímica, troponina sérica, equinos.

¹ Received on April 23, 2023.

Accepted for publication on July 7, 2023.

² Setor de Patologia Veterinária, Departamento de Patologia Clínica Veterinária, Faculdade de Veterinária, Universidade Federal do Rio Grande do Sul (UFRGS), Av. Bento Gonçalves 9090, Prédio 42505, Porto Alegre, RS 91540-000, Brazil. *Corresponding author: cacabpohl@gmail.com

INTRODUCTION

Ionophore antibiotics (IA) have been used in agriculture and animal production systems, such as poultry and cattle, to control coccidia, decrease ketosis, and increase animal growth and weight gain. Commonly used IA are monensin, salinomycin, narasin and lasalocid (O'Brien 2008, Cooper & Valentine 2016). Intoxication usually occurs as a result of an error in feed formulation, use to feed non-target species, association with some drugs that enhance its effects, and ingestion of excessive amounts by dominant animals (Doonan et al. 1989, Bezerra et al. 1999, Bezerra Jr. et al. 2000, Pavarini et al. 2011, Cooper & Valentine 2016, Novilla et al. 2017). Horses are highly susceptible to IA; their feed should not contain these additives. The main lesions reported are cardiomyopathy and necrotic myopathies (Doonan et al. 1989, Bezerra et al. 1999, Pavarini et al. 2011). Cardiovascular lesions induced by IA consumption are often hyperacute and acute, leading to minimal or absent histopathological lesions, making complementary diagnostic techniques essential (Cooper & Valentine 2016).

The correlation between the increase of serum troponin and degenerative cardiomyopathies in horses is part of several studies (Cornelisse et al. 2000, Schwarzwald et al. 2003, Divers et al. 2009, Nath et al. 2012, Ruby et al. 2018). Information on the use of immunohistochemistry (IHC) to detect cardiac lesions in different species is also available (Fishbein et al. 2003, Tunca et al. 2008, Karapinar et al. 2012, Pavarini et al. 2012, Bandinelli et al. 2014). However, information on the serum concentration of cardiac troponin and IHC anti-cTn in naturally IA-intoxicated horses is scarce. Therefore, the present study aimed to analyze the use of serum cardiac troponin I (cTnI) and the immunohistochemistry anti-troponin C (anti-cTnC) as a diagnostic tool for cardiac injuries in horses spontaneously poisoned by salinomycin.

MATERIALS AND METHODS

Clinical and epidemiological data were obtained directly with the stable owner on two on-site visits. Four of seven horses showing clinical signs of weakness underwent postmortem, histopathological and immunohistochemical examination. During the postmortem examination, samples of the main organs, including skeletal muscle (hind limb and forelimb) and cardiac fragments of right and left ventricles, plus right and left papillary muscles, were collected, fixed in 10% buffered formalin, routinely processed for histopathology, and stained by hematoxylin and eosin (HE). Microscopic lesions affecting the heart and skeletal muscles were recorded and graded as mild, moderate, and severe. The procedures described here were conducted in accordance with the Research Committee of the Faculty of Veterinary of the "Universidade Federal do Rio Grande do Sul", Brazil (no. 37662).

Immunohistochemical (IHC) analyses were performed on sections of the heart, using the peroxidase-labeled universal polymer method (MACH 4 HRP-Universal Polymer, Biocare Medical®, Pacheco/CA, USA) for the monoclonal antibody Troponin C (Novo Castra®), dilution 1:40 in PBS (phosphate buffered saline). The antigen retrieval was performed in a digital pressure cooker, pH9 TRIS EDTA buffer - 125°C for 3 minutes. Immunolabelling was visualized using 3-amino-9-ethylcarbazole as chromogen (AEC Romulin, Biocare Medical®, Pacheco/CA, USA), and slides were counterstained with Harris hematoxylin. Myocardium fragments incubated with phosphate-

buffered saline (PBS) instead of the primary antibody served as the negative controls. Myocardial fragments (bearing cardiomyocyte necrosis) from cattle poisoned by *Amorimia exotropica* were used as a positive control (Pavarini et al. 2012, Bandinelli et al. 2014). Immunolabeling was graded according to the decrease in labeling.

Samples of serum from six horses were submitted to measure the concentration of cardiac troponin I (cTnI) 48 to 72 hours after the onset of clinical signs. The enzyme creatine kinase (CK) and aspartate aminotransferase (AST) of Horses 5, 6, and 7, which showed clinical improvement after IA consumption, were also analyzed. The exclusion of Horse 1 from the biochemical analysis was due to severe autolytic changes. The horse's commercial feed was collected and forwarded to quantify monensin and salinomycin using the high-performance liquid chromatography (HPLC) method, according to Official Methods of Analysis of AOAC International (Horwitz & Latimer 2005, Campbell & Nayeri 2006).

RESULTS

Epidemiology and clinical signs

The cases occurred in a property with overnight stables for horses in the municipality of Novo Hamburgo (29°40'40" S; 51°7'51" W), Rio Grande do Sul, Brazil. Of the 42 horses that were on the property, seven were affected. The horse's identification and information are available in Table 1. All the horses were kept mostly indoors and fed a pre-dried base of oats (*Avena sativa*), ryegrass (*Lolium multiflorum*), and commercial feed. The stables owner reported a recent change to a different brand in the commercial ration fed to the horses that present clinical signs five days later. At the onset, there was muscle weakness, locomotor difficulties, breathing distress, and lateral recumbency. Overall, the clinical course lasted approximately 6 to 72 hours. Of the seven affected horses, two died spontaneously (Horses 1 and 2), two were euthanized due to poor prognosis (Horses 3 and 4), and three recovered (Horses 5, 6, and 7). The commercial feed analysis revealed salinomycin in the concentration of 54.71mg/kg (quantification limit 0.7mg/kg), and monensin levels were below the quantification limit (quantification limit 1.40mg/kg) (Horwitz & Latimer 2005, Campbell & Nayeri 2006).

Gross and microscopic findings

Cardiac lesions observed during postmortem examination in the four horses submitted to necropsy were similar in all cases, with varying severity. The lesions were characterized by multifocal to focally extensive pale areas in the myocardium (4/4) (Fig.1), moderate hydropericardium (3/4), and petechiae in the epicardium (3/4). Focally extensive pale areas were

Table 1. Epidemiological aspects of horses intoxicated by salinomycin

Horse	Age	Breed	Sex
1 [‡]	11-years-old	Criollo	M
2 [‡]	4-months-old	Mixed Breed	F
3 [‡]	8-years-old	Mangalarga Marchador	M
4 [‡]	10-years-old	Quarter Horse	M
5 [#]	4-years-old	Quarter Horse	M
6 [#]	5-years-old	Criollo	M
7 [#]	5-months-old	Mixed Breed	F

[‡] Necropsied, [#] recovered; M = male, F = female.

noticed in the skeletal muscle, interspersed with normal musculature, both in appendicular and axial skeletons. These macroscopic changes were evident in the pelvic limbs, mostly on the gluteus muscle, and more pronounced in Horse 4.

Histologically, lesions on cardiac and skeletal muscles corresponded, respectively, to necrotic cardiomyopathy and myopathy. Cardiac alterations included individual and multifocal cardiomyocyte necrosis, characterized by a homogeneous, hypereosinophilic, shrunken cytoplasm, nuclear pyknosis, and occasional karyolysis. Multifocally, intracytoplasmic vacuoles and myofibril fragmentation foci were noticed, associated with infiltrate of macrophages and mild fibroblastic proliferation (Fig.2, 4 and 6). Cardiac lesions were graded according to the severity in mild to moderate (Table 2). Horses with mild cardiac alterations (Horses 1 and 3) presented individual necrosis of cardiomyocytes or small necrotic foci without inflammatory infiltrate. Horses with moderate cardiac alterations (Horses

2 and 4) exhibited accentuated necrosis of cardiomyocytes, associated with few numbers of macrophages and fibroblasts. Myopathy observed in the skeletal muscles was also variable in intensity (mild to moderate). Necrotic lesions were polyphasic and included isolated muscle fibers or small foci characterized by myocyte hypereosinophilia, swelling and loss of striations (hyaline necrosis). Occasionally, there was fragmentation of myofibrils (floccular necrosis) associated with mild infiltrating macrophages.

Immunohistochemistry and serological results

A decreased cTnC expression in the cytoplasm of cardiomyocytes occurred in all cases. Areas histologically characterized for necrosis exhibited accentuated loss or absence of cytoplasmic labeling for cTnC (Fig.3, 5, and 7). The absence of labeling frequently occurred in areas where cardiac lesions were most severe at microscopic examination.

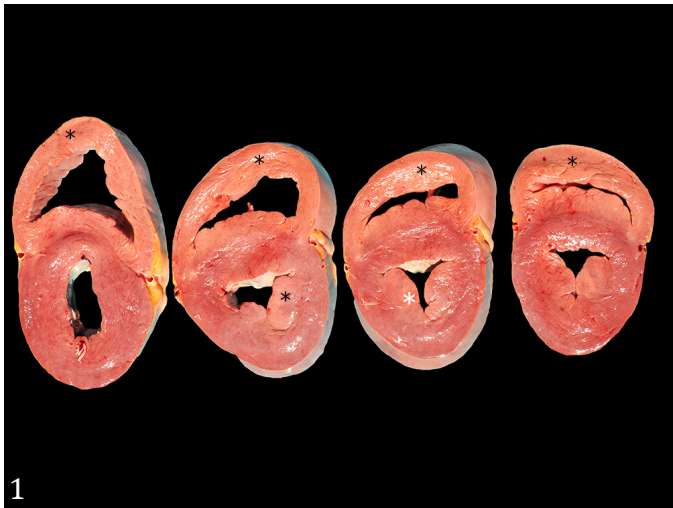

Fig.1. Salinomycin intoxication in horses. Heart cut surface exhibiting focally extensive pale areas in the myocardium (asterisks).

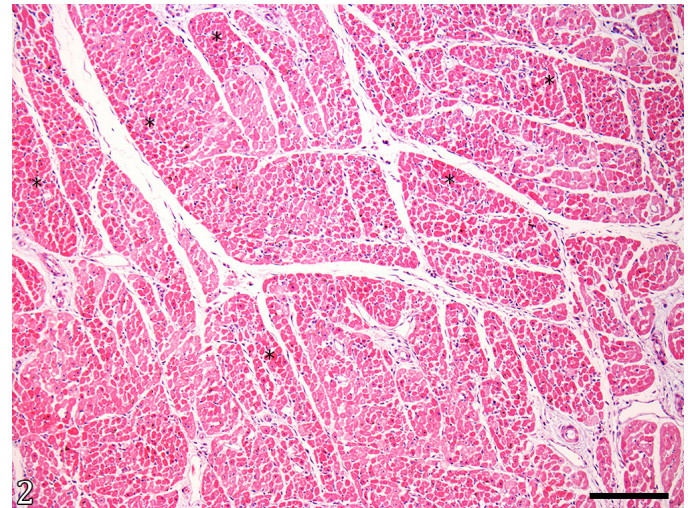


Fig.2. Salinomycin intoxication in horses. Heart. Cardiomyocytes displaying enhanced eosinophilia (asterisks). HE, bar = 500µm.

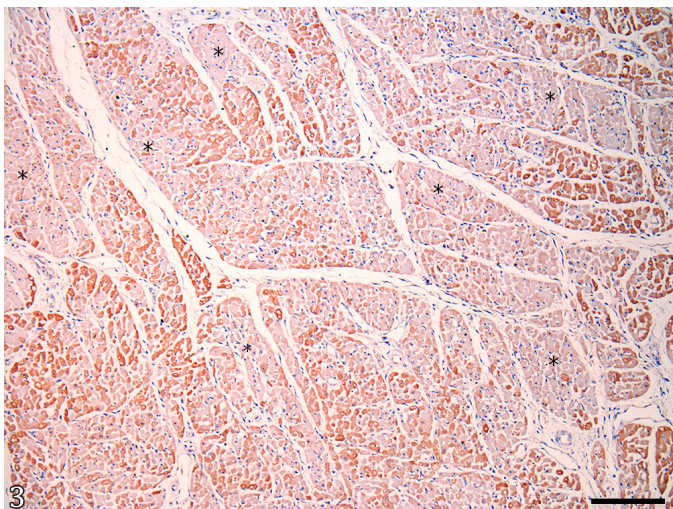


Fig.3. Salinomycin intoxication in horses. Heart. Multifocal areas of decreased anti-cardiac troponin C immunolabeling (asterisks) within the cytoplasm of altered cardiomyocytes who presented hypereosinophilia in Figure 2. AEC, bar = 500µm.

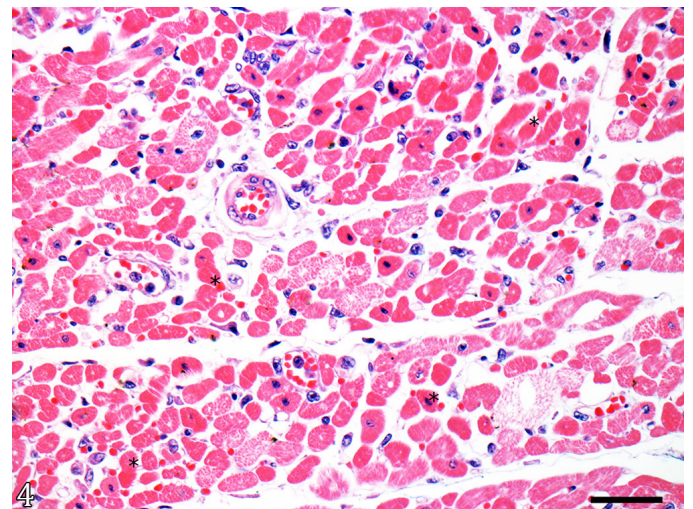


Fig.4. Salinomycin intoxication in horses. Heart. Closer image demonstrating individual necrosis and necrosis of small groups of cardiomyocytes (asterisks). Necrotic cells hypereosinophilic and homogenous cytoplasm, and occasional nuclear pyknosis. HE, bar = 500µm.

However, some areas without histologic lesions also exhibited a lack of labeling for cTnI. The anti-troponin C labeling was intense in the cytoplasm of intact cardiomyocytes from the cases and the cardiac fragments used as controls. Loss or reduction in cytoplasmic labeling in necrotic cells was graded in each horse as mild or moderate. Immunohistochemistry labeling and biochemical analysis are demonstrated in Table 2.

The serum concentration of cTnI was evaluated in six horses (2, 3, 4, 5, 6 and 7). The cTnI varied between 0.005 to 6.573ng/mL (reference value: <0.04ng/mL) (Rossi et al. 2014). The results for the enzyme creatine kinase (CK), and aspartate aminotransferase (AST) were measured in Horses 5, 6 and 7 are available in Table 2.

DISCUSSION

The diagnosis of ionophore poisoning in horses in this study was based on epidemiological, clinical, and laboratory findings added to the detection of salinomycin in the commercial feed ingested by the horses. Salinomycin is considered highly toxic to equines; however, naturally occurring cases are rarely reported (Aleman et al. 2007). Ionophore toxicosis in equines is usually related to the consumption of monensin through the ingestion of other species' feed, e.g., cattle (Doonan et al. 1989, Bezerra

et al. 1999, Pavarini et al. 2012). In the outbreak described here, the horses were fed with commercial feed exclusive for horses, leading to the hypothesis that a mistake in the feed formulation or problems in cleaning the manufacturer's equipment occurred, as already described in the literature in similar outbreaks (Doonan et al. 1989, Bezerra et al. 1999, Cooper & Valentine 2016, Novilla et al. 2017).

The clinical course of IA poisoning is directly related to the consumed dose since extremely high doses can lead to death shortly after consumption, leading to minimal cardiac lesions (Bezerra et al. 1999). The use of IHC for troponin C in the present study was essential for detecting the cardiac lesion in one of the affected horses (Horse 1) since it died with the acute course of the disease, and serum evaluation of cTnI was not possible. In some species of domestic animals, IHC has been used as an auxiliary method of diagnosis in cardiac injuries (Fishbein et al. 2003, Tunca et al. 2008, Karapinar et al. 2012), including the diagnosis of acute cardiotoxic disease in cattle (Pavarini et al. 2012, Bandinelli et al. 2014). IHC is a tool that can be utilized, especially in cases where the serum troponin evaluation is not possible or when the cardiac tissue is already fixed in formalin. Besides that, no data is available regarding the use of IHC anti-cTnI in salinomycin naturally

Table 2. Relation between clinical evolution and histologic lesions in the heart, labeling anti-cTnI, CK and AST in horses intoxicated with salinomycin

Horse	Histology	IHC Anti-cTnI	Troponin I (cTnI) RR: <0.04ng/mL ^A	Creatine kinase (CK) RR: <140U/L ^B	Aspartate aminotransferase (AST) RR: 361 a 1377U/L ^B	Clinical course (after the beginning of the signals)
1 [‡]	+	*	n/a	n/a	n/a	6 hours
2 [‡]	++	**	0.509 ng/mL	n/a	n/a	72 hours
3 [‡]	+	*	0.051 ng/mL	n/a	n/a	48 hours
4 [‡]	++	**	6.573 ng/mL	n/a	n/a	72 hours
5 [#]	n/a	n/a	0.009 ng/mL	359 U/L	361 U/L	72 hours
6 [#]	n/a	n/a	0.156 ng/mL	1153 U/L	1377 U/L	48 hours
7 [#]	n/a	n/a	0.005 ng/mL	503 U/L	662 U/L	48 hours

RR = reference range; ^A Rossi et al. (2014), ^B Kaneko et al. (2008); [‡] necropsy, [#] recovered; n/a = not evaluated; + mild cardiac lesions, ++ moderate cardiac lesions, * mild areas of labeling depletion, ** moderate areas of labeling depletion.

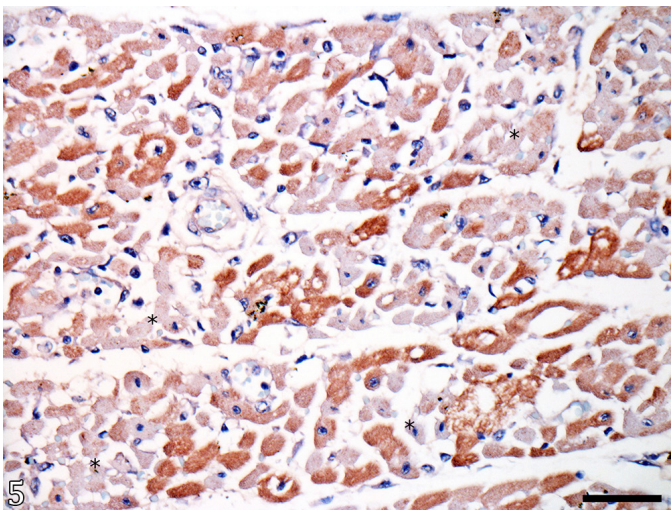


Fig.5. Salinomycin intoxication in horses. Heart. Multifocally, severe absence or decrease in anti-cTnI labeling (asterisks) corresponding to the hyper eosinophilic fibers of Figure 4. AEC, bar = 50µm.

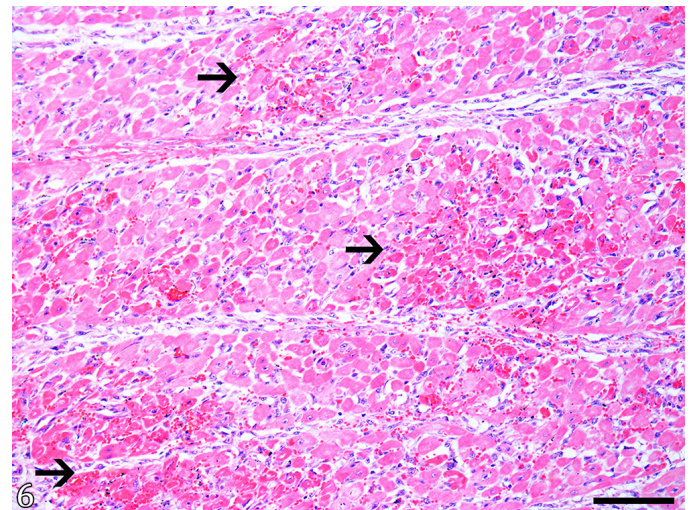


Fig.6. Salinomycin intoxication in horses. Heart. Myocardium of an equine with prolonged clinical evolution (48 hours) exhibiting extensive areas of necrosis of cardiomyocytes (arrows). HE, bar = 100µm.

intoxicated horses. However, the serum dosage of cTnI as an ancillary test for early detection of cardiac lesions in horses may not be enough. This feature may be related to the kinetic liberation of troponin, which consists of two separate intracellular fractions inside the cardiomyocyte. Consequential to the acute cardiac lesion was a liberation of the cytosolic pool, which consists of only 2 to 4% of the cTn within the cell, resulting in an early increase of cTn in blood levels. This event is followed by a slower liberation of structurally bounded troponin, which results in a more long-lasting increase of cTn (Wells & Sleeper 2008, Rossi et al. 2014).

A correlation is suggested between the affected horses' clinical evolution, the histologic lesion's severity, the anti-cTnC labeling, and the serum values of cTnI. Equines with more prominent cardiac lesions and longer clinical courses exhibited higher serum levels of cTnI and well-demarcated areas with a decrease or absence of cTnC expression on IHC. Otherwise, horses that presented less extensive and mild cardiac lesions histologically, with shorter clinical evolution, exhibited mildly decreased areas of cTnC expression on IHC. Besides that, Horse 3 also presented a decreased serum value for cTnI compared to the other horses in this study. Similar data are described in an experimental study conducted with monensin intoxication in horses, which demonstrated an initial increase in serum concentrations of cTnI between 24 and 72 hours after consumption of the compound (Divers et al. 2009). In the same study, two horses that died within one week of exposure due to severe cardiac disease presented higher concentrations of cTnI (Divers et al. 2009). Besides, the serum concentration of cTnI can be proportional to the size of the cardiac lesion, as already noted in dogs (O'Brien et al. 2006), leading to the conclusion that troponin release may be directly related to the degree of myocardial injury.

In humans with myocardial infarction, cTn increases between 4 and 6 hours after the insult to the muscle, and peak values are obtained after 18 to 24 hours (O'Brien 2008, Wells & Sleeper 2008, Rossi et al. 2014). Similar data can be suggested in horses since nucleotide and amino acid sequence exhibits greater than 90% homology between human and

equine cTnI (Rishniw & Simpson 2005). Another feature that must be considered includes the association between high cTnI levels and the prognostic value of these levels in horses with cardiac disease (Nath et al. 2012). This feature is interesting since one of the horses described here (Horse 6) presented increased cTnI but had clinical recovery. In contrast, Horse 3 presented lower cTnI values evolved to death. A similar case is described in a study where a horse survived after presenting a high serum cTnI (Nath et al. 2012).

Other markers can be used to diagnose cardiac disease in horses (Rossi et al. 2014). In this study, CK and AST were measured in three recovered horses, in which Horse 6 presented a significant enzyme increase. However, these enzymes lack tissue specificity for diagnosing heart disease since they are also present in skeletal muscle and liver (Schwarzwalder et al. 2003, Nath et al. 2012, Rossi et al. 2014, Ruby et al. 2018). Therefore, the presented results suggest that the mensuration of cTnI can be sensitive to clinical evaluation and detection of myocardial disease in horses suspected to be intoxicated with ionophores. Differential diagnosis of IA intoxication in horses must include diseases characterized as cardiomyopathy and/or myopathy, such as exertional rhabdomyolysis and poisoning by *Senna occidentalis* (Irigoyen et al. 1991). The epidemiological findings and the IA identification in the commercial feed were essential to make the diagnosis.

CONCLUSIONS

The serum detection of cardiac troponin I (cTnI) can be considered a good marker to determine cardiac damage in horses intoxicated with salinomycin with a clinical evolution of 48 hours or more. The anti-cTnC IHC aided in detecting cardiac injury in horses independent of clinical evolution.

Cardiomyocytes, histologically characterized by cellular death, had an absence of cTnC labeling, which demonstrates the sensitivity of this human marker in horses.

Regarding the prognostic value of these tests, more research is necessary to correlate serum determination of cTnI with the survival of horses with toxic cardiac lesions.

Authors' contributions. - C.B. Pohl, B.S. Cecco, L.C. Henker, M.B. Bandinelli, R.M. Bianchi, W. Panziera, S.P. Pavarini and D. Driemeier contributed to the collection of the samples, made a substantial contribution to the gross, histopathological analysis, drafted and revised the manuscript and its final version.

Acknowledgments. - The authors are grateful to the "Conselho Nacional de Desenvolvimento Científico e Tecnológico" (CNPq). This study was partially funded by the "Coordenação de Aperfeiçoamento de Pessoal de Nível Superior" (CAPES), Brazil - Finance Code 001.

Conflict of interest statement. - The authors declare having no conflicts of interest.

REFERENCES

- Aleman M., Magdesian K.G., Peterson T.S. & Galey F.D. 2007. Salinomycin toxicosis in horses. *J. Am. Vet. Med. Assoc.* 230(12):1822-1826. <<https://dx.doi.org/10.2460/javma.230.12.1822>> <PMid:17571983>
- Bandinelli M.B., Bassuino D.M., Fredo G., Mari C., Driemeier D., Sonne L. & Pavarini S.P. 2014. Identificação e distribuição de lesões cardíacas em bovinos intoxicados por *Amorimia exotropicalis*. *Pesq. Vet. Bras.* 34(9):837-844. <<https://dx.doi.org/10.1590/S0100-736X2014000900006>>

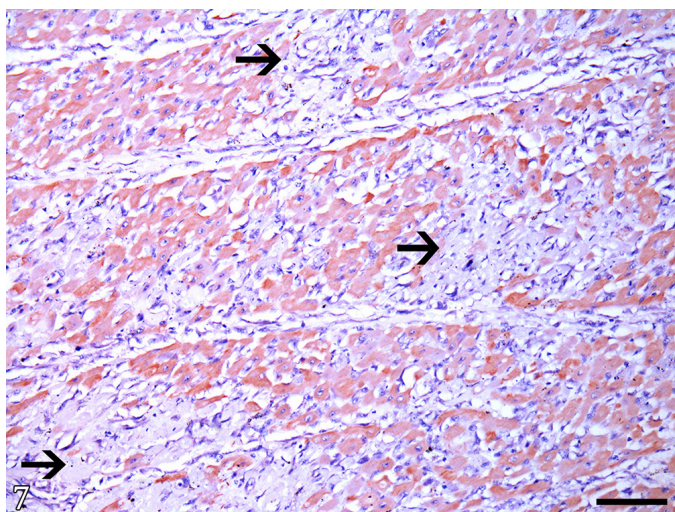


Fig.7. Salinomycin intoxication in horses. Heart. Marked absence of labeling anti-cTnC (arrows) in areas corresponding to the necrotic foci from the Figure 6. AEC, bar = 100µm.

- Bezerra Jr. P.S., Ilha M.R.S, Langohr I.M. & Barros C.S.L. 2000. Intoxicação experimental por monensina em eqüinos. *Pesq. Vet. Bras.* 20(3):102-108. <<https://dx.doi.org/10.1590/S0100-736X2000000300003>>
- Bezerra P.S., Driemeier D., Loretti A.P., Riet-Correa F., Kamphues J. & Barros C.S.L. 1999. Monensin poisoning in Brazilian horses. *Vet. Hum. Toxicol.* 41(6):383-385. <PMid:10592947>
- Campbell H. & Nayeri G. 2006. Determination of monensin, narasin, and salinomycin in mineral premixes, supplements, and animal feeds by liquid chromatography and post-column derivatization: collaborative study. *J. AOAC Int.* 89(5):1229-1242. <<https://dx.doi.org/10.1093/jaoac/89.5.1229>> <PMid:17042170>
- Cooper B.J. & Valentine B.A. 2016. Muscle and tendon, p.164-249. In: Maxie M.G. (Ed.), Jubb, Kennedy, and Palmer's Pathology of Domestic Animals. Vol.2. 6th ed. Elsevier, St. Louis.
- Cornelisse C.J., Schott II H.C., Olivier N.B., Mullaney T.P., Koller A., Wilson D.V. & Derkser F.J. 2000. Concentration of cardiac troponin I in a horse with a ruptured aortic regurgitation jet lesion and ventricular tachycardia. *J. Am. Vet. Med. Assoc.* 217(2):231-235. <<https://dx.doi.org/10.2460/javma.2000.217.231>> <PMid:10909465>
- Divers T.J., Kraus M.S., Jesty S.A., Miller A.D., Mohammed H.O., Gelzer A.R.M., Mitchell L.M., Soderholm L.V. & Ducharme N.G. 2009. Clinical findings and serum cardiac troponin I concentrations in horses after intragastric administration of sodium monensin. *J. Vet. Diagn. Invest.* 21(3):338-343. <<https://dx.doi.org/10.1177/104063870902100305>> <PMid:19407085>
- Doonan G.R., Brown C.M., Mullaney T.P., Brooks D.B., Ulmanis E.G. & Slanker M.R. 1989. Monensin poisoning in horses—an international incident. *Can. Vet. J.* 30(2):165-169. <PMid:17423238>
- Fishbein M.C., Wang T., Matijasevic M., Hong L. & Apple F.S. 2003. Myocardial tissue troponins T and I: an immunohistochemical study in experimental models of myocardial ischemia. *Cardiovasc. Pathol.* 12(2):65-71. <[https://dx.doi.org/10.1016/S1054-8807\(02\)00188-6](https://dx.doi.org/10.1016/S1054-8807(02)00188-6)> <PMid:12684160>
- Horwitz W. & Latimer Jr. W. (Ed.), 2005. Official Methods of Analysis of AOAC International. 18th ed. Current through revision 1, 2006. AOAC International, Gaithersburg, 28p.
- Irigoyen L.F., Graça D.L. & Barros C.S.L. 1991. Intoxicação experimental por *Cassia occidentalis* (Leg. Caes.) em eqüinos. *Pesq. Vet. Bras.* 11(1/2):35-44.
- Kaneko J.J., Harvey J.W. & Bruss M.L. 2008. Clinical Biochemistry of Domestic Animals. 6th ed. Academic Press, Massachusetts. 936p. <<https://dx.doi.org/10.1016/B978-0-12-370491-7.X0001-3>>
- Karapinar T., Eroksuz Y., Beytut E., Sozduitmaz I., Eroksuz H. & Dabak M. 2012. Increased plasma cardiac troponin I concentration in lambs with myocarditis. *Vet. Clin. Pathol.* 41(3):375-381. <<https://dx.doi.org/10.1111/j.1939-165X.2012.00448.x>> <PMid:22747688>
- Nath L.C., Anderson G.A., Hinchcliff K.W. & Savage C.J. 2012. Serum cardiac troponin I concentrations in horses with cardiac disease. *Aust. Vet. J.* 90(9):351-357. <<https://dx.doi.org/10.1111/j.1751-0813.2012.00970.x>> <PMid:22928683>
- Novilla M.N., Mcclary D. & Laudert S.B. 2017. Ionophores, p.503-518. In: Gupta R.C. (Ed.), Reproductive and Developmental Toxicology. 2nd ed. Academic Press, Massachusetts.
- O'Brien P.J. 2008. Cardiac troponin is the most effective translational safety biomarker for myocardial injury in cardiotoxicity. *Toxicology* 245(3):206-218. <<https://dx.doi.org/10.1016/j.tox.2007.12.006>> <PMid:18249481>
- O'Brien P.J., Smith D.E.C., Knechtel T.J., Marchak M.A., Pruiimboom-Brees I., Brees D.J., Spratt D.P., Archer F.J., Butler P., Potter A.N., Provost J.P., Richard J., Snyder P.A. & Reagan W.J. 2006. Cardiac troponin I is a sensitive, specific biomarker of cardiac injury in laboratory animals. *Lab. Anim.* 40(2):153-171. <<https://dx.doi.org/10.1258/002367706776319042>> <PMid:16600075>
- Pavarini S.P., Bandinelli M.B., Juffo G.D., Souza S.O., Driemeier D. & Cruz C.E.F. 2012. Decreased expression of cardiac troponin C is associated with cardiac lesions in *Amorimia exotropa* poisoned cattle. *Pesq. Vet. Bras.* 32(10):1005-1008. <<https://dx.doi.org/10.1590/S0100-736X2012001000010>>
- Pavarini S.P., Wouters F., Bandarra P.M., Souza F.S., Dalto A.G.C., Gomes D.C., Cruz C.E.F. & Driemeier D. 2011. Surto de intoxicação por monensina em avestruzes e eqüinos no sul do Brasil. *Pesq. Vet. Bras.* 31(10):844-850. <<https://dx.doi.org/10.1590/S0100-736X2011001000003>>
- Rishniw M. & Simpson K.W. 2005. Cloning and sequencing of equine cardiac troponin I and confirmation of its usefulness as a target analyte for commercial troponin I analyzers. *J. Vet. Diagn. Invest.* 17(6):582-584. <<https://dx.doi.org/10.1177/104063870501700611>> <PMid:16475519>
- Rossi T.M., Pyle W.G., Maxie M.G., Pearl D.L. & Physick-Sheard P.W. 2014. Troponin assays in the assessment of the equine myocardium. *Equine Vet. J.* 46(3):270-275. <<https://dx.doi.org/10.1111/evj.12209>> <PMid:24215569>
- Ruby R.E., Wong D.M., Ware W.A. & Ackermann M.R. 2018. Myocardial fibrosis and ventricular tachyarrhythmia in a thoroughbred filly. *J. Equine. Vet. Sci.* 70:107-111. <<https://dx.doi.org/10.1016/j.jevs.2018.08.006>>
- Schwarzwalz C.C., Hardy J. & Buccellato M. 2003. High cardiac troponin I serum concentration in a horse with multiform ventricular tachycardia and myocardial necrosis. *J. Vet. Intern. Med.* 17(3):364-368. <<https://dx.doi.org/10.1111/j.1939-1676.2003.tb02464.x>>
- Tunca R., Sozmen M., Erdogan H., Cital M., Uzlu E., Ozen H. & Gokçe E. 2008. Determination of cardiac troponin I in the blood and heart of calves with foot-and-mouth disease. *J. Vet. Diagn. Invest.* 20(5):598-605. <<https://dx.doi.org/10.1177/104063870802000510>> <PMid:18776092>
- Wells S.M. & Sleeper M. 2008. Cardiac troponins. *J. Vet. Emerg. Crit. Care* 18(3):235-245. <<https://dx.doi.org/10.1111/j.1476-4431.2008.00307.x>>