

# RENAL AND CUTANEOUS SYSTEMIC VASCULITIS IN PATIENTS ADDICTED TO COCAINE-LEVAMISOLE: A MISSED DIAGNOSIS?

Francisco V. Veronese<sup>1</sup>, Gustavo G. Thomé<sup>1</sup>, Thiago Pereira Itaquy<sup>1</sup>, Elisa Fulber<sup>1</sup>, Lorenzo Casagrande<sup>1</sup>, William C. da Silva<sup>1</sup>, Henrique Garbin<sup>1</sup>, Viviane Sebben<sup>2</sup>, Alberto Nicoletta<sup>2</sup>, Elvino J. G. Barros<sup>1</sup>

<sup>1</sup>Division of Nephrology, Hospital de Clínicas de Porto Alegre, Universidade Federal do Rio Grande do Sul, Porto Alegre, Brazil  
<sup>2</sup>Toxicological Information Center of Rio Grande do Sul, Porto Alegre, Brazil.

## Introduction and Aims

- Adulterated cocaine/levamisole has been increasingly used during the last decades around the world.
- Levamisole can cause skin lesions, intravascular thrombosis, neutropenia, and renal involvement, which are frequently missed in the clinical evaluation of these patients.
- Increased patient and physician awareness is essential to ensuring proper diagnosis and treatment.

## Methods

- We describe a series of five cases in patients of southern Brazil who were chronic users of cocaine/levamisole and presented skin lesions and/or acute kidney injury.
- Patient's medical records were reviewed and demographic, clinical and laboratorial data were extracted.
- Serial urine samples were collected for cocaine and levamisole toxicological analysis; the samples were analyzed by immunochromatographic drug screen test (Abon, Biopharm, China). Confirmatory testing was performed by gas-chromatography-mass spectrometry (GC/MS) in an Agilent 7890A/5975C system (Wilmington, DE, USA).

**Table 1: Clinical presentation and outcome of the patients**

	1 - Female, 46y	2 - Male, 48y	3 - Male, 48y	4 - Male, 50y	5 - Female, 22y
Creatinine	0,8 mg/dL	Dialysis need	2,7 mg/dL	4,8 mg/dL	3,4 mg/dL
UPCR	0,01	6,6	0,66	0,67	1,8
Hematuria	None	Microscopic	Microscopic	Microscopic	Microscopic
Renal Biopsy	Not performed	Pauci-immune crescentic glomerulonephritis	Pauci-immune crescentic glomerulonephritis	Pauci-immune crescentic glomerulonephritis	Pauci-immune crescentic glomerulonephritis
Skin manifestations	Retiform purpura in lower and upper limbs Hemorrhagic vesicles	Retiform purpura in lower and upper limbs Oral ulcer	None	Retiform purpura in lower limbs Focal necrosis in ear lobes	Retiform purpura in lower limbs
Skin Biopsy	Leukocytoclastic vasculitis	Leukocytoclastic vasculitis	Not performed	Leukocytoclastic vasculitis	Not performed
Other manifestations	Arthritis	Retinal vasculitis Arthritis	Arthralgia	None	Abdominal pain Arthralgia
Serology	pANCA >1/320	pANCA 1/320	pANCA >1/320 ANF1/320 nuclear dot	pANCA >1/320 Positive anti-MPO and anti-PR3	pANCA >1/320 ANF1/320 nuclear dot
Treatment	Oral Prednisone	Methylprednisolone Cyclophosphamide Plasmapheresis	Methylprednisolone Cyclophosphamide	Methylprednisolone Cyclophosphamide	Methylprednisolone Cyclophosphamide
Outcome	Death (sepsis)	ESRD in hemodialysis No skin lesions	Cr 1,2 mg/dL No proteinuria	Cr 1,5 mg/dL UPCR 0,2 No skin lesions	Cr 0,9 mg/dL UPCR 3,0 No skin lesions
Cocaine use	Used until death	Still in use	Still in use	Abstinent	Still in use

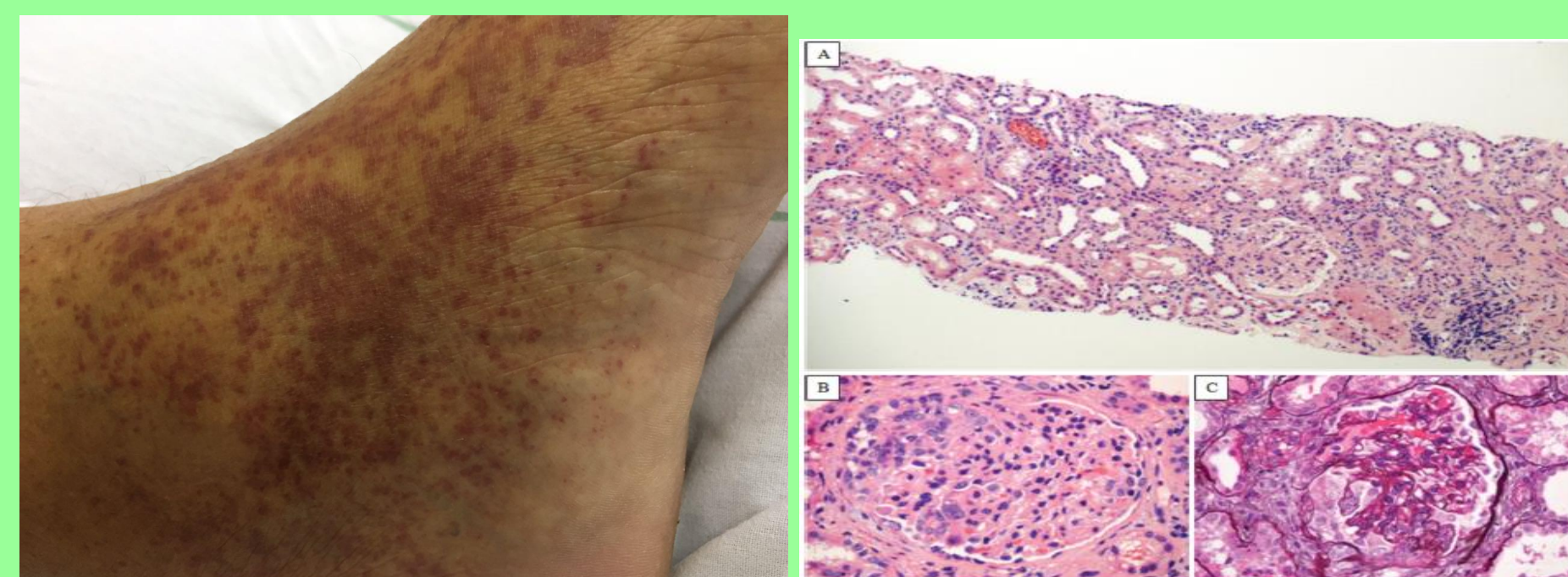
UPCR = urinary protein/creatinine ratio; pANCA = perinuclear anti-neutrophil cytoplasmic antibody; ANF = antinuclear factor; Anti-MPO = anti-myeloperoxidase; Anti-PR3 = anti-proteinase 3; ESRD = end-stage renal disease

## Results

- Patients characteristics and follow up are shown in table 1. Four patients exhibited retiform purpura in extremities (Fig.1), and one of them had focal skin necrosis in the ear lobes. Four had elevated serum creatinine, proteinuria, severe anemia, and all patients had positive circulating anti-neutrophil cytoplasmic antibodies (ANCA). In one patient it was possible to measure serum anti-myeloperoxidase and anti-proteinase 3 antibodies, and both were positive. The four patients with renal manifestations were submitted to percutaneous kidney biopsy that showed pauci-immune crescentic glomerulonephritis, with glomerular crescents, necrosis, and diffuse inflammation (Fig.2).
- The presence of levamisole and cocaine in serial urine samples was confirmed in all five patients. The patients were advised to quit cocaine use, but only one stopped the illicit drugs, as confirmed in subsequent measurements.
- Four of the patients were treated with immunosuppressive therapy consisting of corticosteroids and monthly intravenous pulses of cyclophosphamide, due to the severity of the crescentic glomerulonephritis.
- One patient developed end-stage renal disease, requiring renal replacement therapy. The patient with vasculitis restricted to skin was later admitted with acute kidney injury and mesenteric ischemia (still in use of cocaine), and died in the second day of hospitalization from a septic shock due to intestinal perforation. The other three patients showed improved renal function during treatment, with in hospital serum creatinine varying from 2,7 to 4,8 mg/dL, and in outpatient follow-up varying from 0,9 to 1,5 mg/dL. Three of four patients with renal vasculitis maintained cocaine/levamisole abuse as confirmed by urine sample analysis, despite their referred abstinence. The only patient with confirmed abstinence remitted the clinical manifestations.

## Conclusions

- Cocaine/levamisole-induced vasculitis should be suspected in the presence of acute renal failure and skin lesions, even when drug abuse is denied, and especially when associated with retiform purpura.
- A urine drug toxicology screen is necessary to confirm the diagnosis and must be done during patient follow-up to ascertain drug abstinence.
- Drug abstinence, and in selected cases immunosuppressive therapy, are the best treatment strategy, and they seem to be associated with better clinical outcomes.



**Figure 1: Retiform purpura**

**Figure 2: Crescentic glomerulonephritis**

## References

1. Lee KC, Ladizinski B, Federman DG. Complications Associated With Use of Levamisole-Contaminated Cocaine: An Emerging Public Health Challenge. *Mayo Clin Proc* 2012; 87: 581-586.
2. Arora NP, Jain T, Bhanot R, Natesan SK. Levamisole-induced leukocytoclastic vasculitis and neutropenia in a patient with cocaine use: an extensive case with necrosis of skin, soft tissue, and cartilage. *Addict Sci Clin Pract* 2012; 7:19-28.
3. Carlson AQ, Tout DS, Jen KY, Butcher B, Graf J, Sam R, et al. Pauci-Immune glomerulonephritis in individuals with disease associated with levamisole-adulterated cocaine: a series of 4 cases. *Medicine (Baltimore)* 2014; 93: 290-297.