

Histopathological changes in the kidneys of vertebrate hosts infected naturally and experimentally with *Paratanaisia bragai* (Trematoda, Digenea)

Mudanças histopatológicas nos rins de hospedeiros vertebrados naturalmente e experimentalmente infectados com *Paratanaisia bragai* (Trematoda, Digenea)

Vanessa Barreto Xavier¹; Aleksandra Oliveira-Menezes²; Marcos Antônio José dos Santos³; Suzana Bencke Amato⁴; Eduardo José Lopes Torres⁵; Jairo Pinheiro^{1,6*}; Solange Viana Paschoal Blanco Brandolini³

¹Pós-Graduação em Ciências Veterinárias, Departamento de Parasitologia Animal, Instituto de Veterinária, Universidade Federal Rural do Rio de Janeiro – UFRRJ, Seropédica, RJ, Brasil

²Universidade Federal do Rio de Janeiro – UFRJ, Polo Barreto, Campus Macaé, RJ, Brasil

³Departamento de Biologia Animal, Instituto de Biologia, Universidade Federal Rural do Rio de Janeiro – UFRRJ, Seropédica, RJ, Brasil

⁴Departamento de Zoologia, Instituto de Biociências, Universidade Federal do Rio Grande do Sul – UFRGS, Porto Alegre, RS, Brasil

⁵Departamento de Imunologia, Microbiologia e Parasitologia, Faculdade de Ciências Médicas, Universidade do Estado do Rio de Janeiro – UERJ, Rio de Janeiro, RJ, Brasil

⁶Departamento de Ciências Fisiológicas, Instituto de Biologia, Universidade Federal Rural do Rio de Janeiro – UFRRJ, Seropédica, RJ, Brasil

Received December 1, 2014

Accepted February 6, 2015

Abstract

Paratanaisia bragai is a trematode parasite that reaches sexual maturity in the kidney collecting ducts of domesticated and wild fowl and whose intermediate hosts are the snails *Subulina octona* and *Leptinaria unilamellata*. There are some discrepancies in descriptions of the pathology of this parasite in bird kidneys. Therefore, the purpose of this study was to analyze the kidneys of rock pigeons (*Columba livia*) naturally infected and of chickens (*Gallus gallus*) experimentally infected with *Paratanaisia bragai*, by means of macroscopic observation and by light and scanning electron microscopy. Both bird species showed significantly dilated collecting ducts. In addition, lymphocyte infiltration was observed in the kidneys of *C. livia* and metaplasia in the epithelial lining of the kidney collecting ducts of *G. gallus*.

Keywords: *Paratanaisia bragai*, *Columba livia*, kidney, histopathology.

Resumo

Paratanaisia bragai é um trematódeo que atinge sua maturidade sexual nos ductos coletores de rins de aves domésticas e silvestres, tendo os moluscos *Subulina octona* e *Leptinaria unilamellata* como hospedeiros intermediários. A patologia descrita no rim das aves apresenta uma série de divergências. Dessa forma, o presente estudo teve como objetivo analisar rins de *Columba livia*, naturalmente infectada, e de *Gallus gallus* infectados experimentalmente por *Paratanaisia bragai*. Através das análises, verificaram-se alterações macroscópicas, por microscopia de luz e eletrônica de varredura, sendo caracterizada significativa dilatação dos túbulos coletores. Essas alterações foram observadas nas aves infectadas naturalmente e experimentalmente. Por outro lado, foi observada infiltração linfocitária nos rins de *C. livia*, naturalmente infectada, e ocorrência de metaplasia no revestimento epitelial dos túbulos coletores dos rins de *G. gallus*, experimentalmente infectados.

Palavras-chave: *Paratanaisia bragai*, *Columba livia*, rim, histopatologia.

*Corresponding author: Jairo Pinheiro. Departamento de Ciências Fisiológicas, Instituto de Biologia, Universidade Federal Rural do Rio de Janeiro – UFRRJ, BR465, km 7, CEP 23.890-000, Seropédica, RJ, Brasil.
e-mail: jairopinheirodasilva@gmail.com

Introduction

Paratanaisia bragai (Santos, 1934) Freitas, 1959 is a trematode that reaches sexual maturity in the kidney collecting ducts of domesticated and wild fowls. Its main intermediate host for larval development is the snail *Subulina octona* (Bruguière, 1798), although there is also a report of *Leptinaria unilamellata* (d'Orbigny, 1837) acting as an intermediate host in Brazil (BRANDOLINI et al., 1997).

The embryonated eggs, which are eliminated in the host's excretory products, passively infect the mollusk. After the miracidium hatches, two generations of sporocysts develop within the snail, cercariae and metacercariae. The definitive host acquires the infection by eating the parasitized mollusk (MALDONADO, 1945; KELLER & ARAÚJO, 1992; BRANDOLINI & AMATO, 2006).

Infection with *Paratanaisia bragai* is common in poultry in the state of Rio de Janeiro (GOMES et al., 2005). This parasite has low pathogenicity, which is indicated by the presence of mild intensity infection with no inflammatory reaction, according to Pinto et al. (2004). However, a high parasite load can cause development of renal monostomosis with mucoid, blood, diarrhea, and even death (ARNIZAUT et al., 1992).

Wild birds infected with *P. bragai* probably act as reservoirs because they often come into proximity by eating the same food as chickens kept outdoors (GOMES et al., 2005). Migratory wild birds with trematode infections with can also spread helminths to new areas, representing a significant risk of native hosts being exposed to infection (ATKINSON et al., 2008). These factors render *P. bragai* of veterinary importance, because infection with this parasite can cause economic losses if it results in serious lesions or death of the host.

Several authors have reported histopathological alterations caused by the presence of *P. bragai* in the kidney collecting tubules of domesticated and wild birds. Macroscopic changes have also been reported in *Columba livia* Gmelin, 1789 and *Gallus gallus* (Linnaeus, 1758) by Barretto & Mies Filho (1942), in *Meleagris gallopavo* Linnaeus, 1758 and *C. livia* by Portugal et al. (1972), and in *Columba inornata wetmorei* Peters, 1937 by Arnizaut et al. (1992). However, several authors did not observe macroscopic alterations in all bird species infected with *P. bragai*, such as Menezes et al. (2001) in *Numida meleagris* (Linnaeus, 1758) and Pinto et al. (2004) in *Columbina talpacoti* (Temminck, 1811).

A few articles have reported the symptomatology resulting from infection with *P. bragai*. These symptoms involve weight loss, intermittent bloody mucoid diarrhea, occasional hemorrhaging, physical weakness, drowsiness and ruffled feathers (PORTUGAL et al., 1972; ARNIZAUT et al., 1992; KUMAR et al., 2009). Histopathological alterations have also been reported. Arnizaut et al. (1992) observed interstitial infiltrate of inflammatory cells inside the renal tubules, composed of heterophils and eosinophils, while Brener et al. (2006) reported similar alterations, including a discrete heterophilic infiltrate.

Because of the divergent findings regarding both macroscopic and microscopic pathologies attributable to *P. bragai*, the aim of this study was to make a comparative analysis of the macroscopic and microscopic changes in the kidneys of *C. livia* naturally infected and *G. gallus* experimentally infected with *P. bragai*.

Materials and Methods

Source of the pigeons and chickens

Adult *C. livia* pigeons were caught in the city of Seropédica, state of Rio de Janeiro, Brazil (22° 49' 36" S and 43° 38' 15" W) and also in the Irajá district of the city of Rio de Janeiro (22° 49' 51" S and 43° 20' 17" W). The chickens (*G. gallus*, Rhode breed, 21-day-old chicks) were purchased from a breeder in the Seropédica city, located near the site where the pigeons were captured.

Experimental procedures

In the laboratory, the pigeons were subjected to fecal examination to detect infection. Four pigeons, three infected and one uninfected one (control) were euthanized in a CO₂ chamber and necropsied for the removal of their kidneys, which were placed in Petri dishes containing a physiological solution of 0.85% sodium chloride (NaCl) and left there until they were sectioned by scalpel (BRANDOLINI, 2000).

The research ethics committee of the Federal Rural University of Rio de Janeiro (UFRRJ) under protocol number 186/2011 and process number 23011596/2011-67 approved the experimental protocols.

The chicks were experimentally infected by oral administration of visceral mass from *S. octona* and *L. unilamellata* snails containing *P. bragai* metacercariae.

To detect the first eggs from the infected chicks, Ritchie's fecal sedimentation method was used (as described by DE CARLI, 1994), starting on the 15th day of the experiment. After confirmation of the conclusion of the prepatent period by the fecal examination, the chicks were euthanized and necropsied, following the same procedure as that used on the pigeons.

Histological procedures

Kidney fragments from both bird species were fixed in Duboscq-Brasil fluid (FERNANDES, 1949) and processed by the routine histological technique (HUMASON, 1979). A Spencer 820 microtome (American Optical Co.) was used to obtain 5-µm sections, which were stained with hematoxylin-eosin and Gomori trichrome (Luna, 1968) and mounted on slides. Photomicrographs of the tissues were recorded using an Olympus DO12 digital image system coupled to an Olympus BX51 light microscope.

Electron microscopy of the histological slides

Tissue sections processed as described for the histological analysis were collected on coverslips, deparaffinized, gold-coated (10-15 nm thick layer) and analyzed under a FEI-Quanta 250 scanning electron microscope (SEM) operating in high vacuum mode with an acceleration voltage of 15 kV.

Results

In this study, we did not observe any symptoms in the birds parasitized by *P. bragai* that could be related to the infection, despite high intense infection.

In the macroscopic examination of the kidneys of *C. livia* naturally infected with *P. bragai*, some of the kidneys showed discrete dilation due to the presence of parasites in the collecting

tubules. In the kidney sections, we observed a brownish coloration in the medullar region due to the presence of *P. bragai* inside the collecting tubules. However, the dilation observed in this study is not a recurring pattern of the macroscopic lesions observed in the kidneys of birds parasitized by *P. bragai*.

The microscopic examination of the histological sections of the kidneys of naturally infected *C. livia* showed substantial dilation and obstruction of the renal tubules (Figure 1a), with epithelial

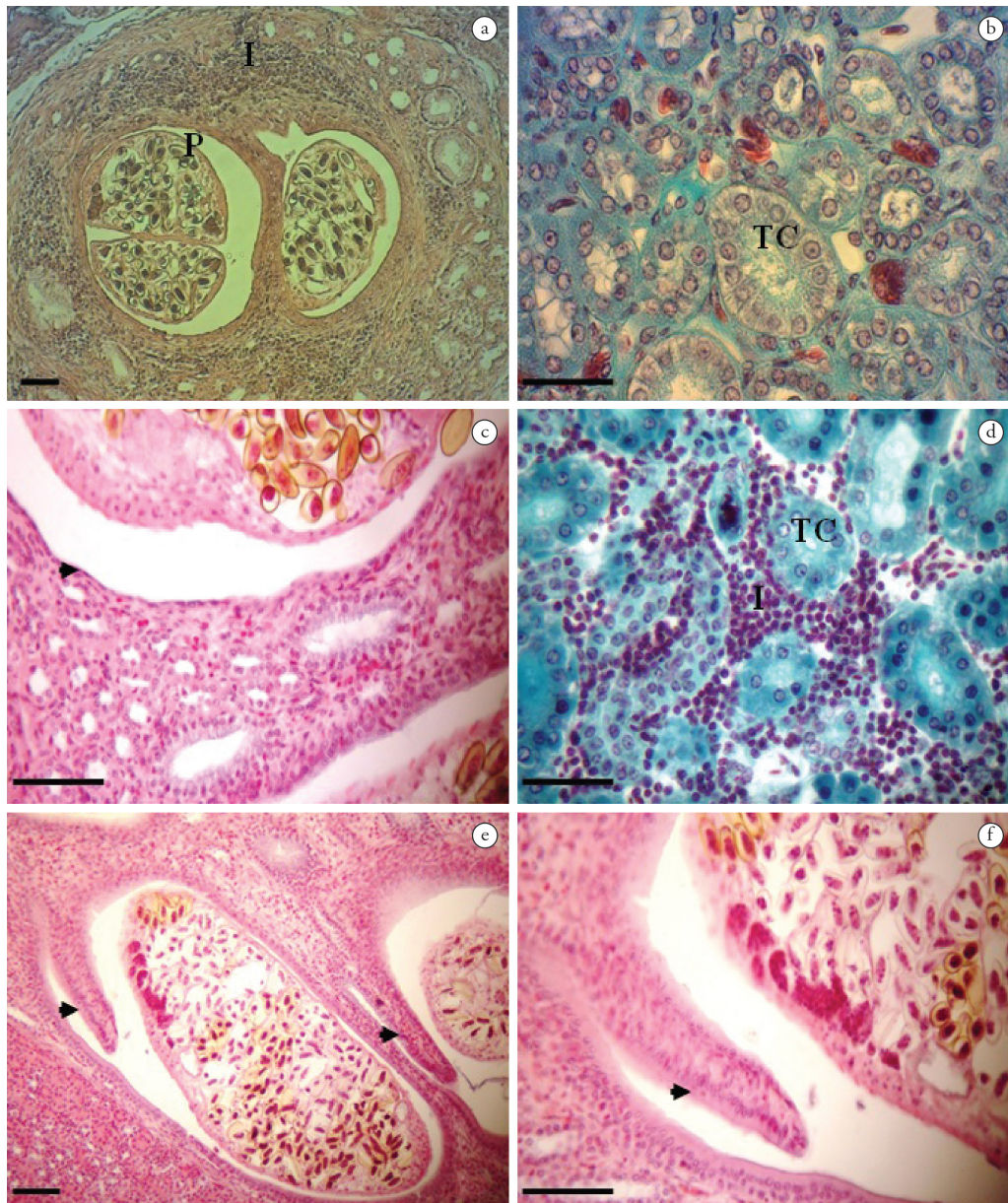


Figure 1. Kidney of *Columba livia*. **1a.** Medullar region of a kidney naturally infected with *Paratanaisia bragai*, showing collecting tubules dilated by the presence of the parasite (P) and an inflammatory process (I) surrounding the tubule. Hematoxylin-eosin. Scale bar = 50 μ m. **1b.** Medullar region of an uninfected kidney, showing the collecting tubules (CT) with simple cuboidal epithelium. Gomori trichrome. Scale bar = 20 μ m. **1c.** Flattening (arrow) of the tubular epithelium (metaplasia) of a kidney from an experimentally infected *G. gallus*, which changed from simple cuboidal to simple squamous. Hematoxylin-eosin. Scale bar = 20 μ m. **1d.** Inflammatory process (I) with mononuclear cells (multifocal interstitial nephritis) in a kidney from *C. livia*. Gomori trichrome. Scale bar = 20 μ m. **1e.** Kidney collecting tubules from experimentally infected *G. gallus*, with formation of a digitiform structure (papilliform formation) projecting in the tubular lumen. Hematoxylin-eosin. Scale bar = 50 μ m. **1f.** Detail of the papilliform formation. Hematoxylin-eosin. Scale bar = 20 μ m.

hyperplasia due to the presence of *P. bragai*. The kidney collecting tubules of the uninfected *C. livia* were also found to be lined with simple cuboidal epithelium, as can be seen in Figure 1b.

There was flattening of the tubular epithelium of the kidneys of the experimentally infected chicks, which changed from simple cuboidal to simple squamous (Figure 1c). An inflammatory process with mononuclear cells (multifocal interstitial nephritis) was visible in the interstitial renal tissue (Figure 1d), and also surrounding the parasitized collecting tubules, some of them showing destruction of the epithelium (Figure 1a). The collecting tubules of the parasitized chicks exhibited epithelial hyperplasia with papillary pattern projecting in the tubular lumen (Figures 1e, f), as well as proliferation of connective tissue surrounding the parasitized tubules and congestion of vessels.

The occurrence of metaplasia in the epithelium of the collecting tubule walls, from simple cuboidal to pseudostratified to prismatic, was observed in *C. livia* naturally infected and in *G. gallus* experimentally infected with the parasite (Figure 2a, b, c). The metaplasia was slightly observed in light microscopy, and the change from simple cuboidal to pseudostratified epithelium was confirmed by SEM examination of the histological sections of the infected kidneys, where nuclei of tubule wall cells of different heights were clearly visible.

Discussion

The symptomatology of infection with *P. bragai* in various bird species has been reported in the literature, including the findings of Arnizaut et al. (1992), who observed weight loss and intermittent bloody mucoid diarrhea, resulting in the death of some animals. Likewise, Unwin et al. (2013) reported the death of *Zenaida graysoni* Lawrence, 1871 and suggested this was caused by infection with *P. bragai*, because the birds exhibited severe renal lesions. Kumar et al. (2009) found occasional hemorrhaging in the kidneys of *C. livia* parasitized by *P. bragai*. Other symptoms were described by Portugal et al. (1972), such as weakening, drowsiness and ruffled feathers. After these symptoms appeared, the pigeons died. The authors also described the presence of a polycystic kidney, with cysts containing a clear liquid and granular substance. Similarly, Kumar et al. (2009) observed nodular growths resulting from hemorrhages in the kidneys of *C. livia* parasitized by *P. bragai*. We did not observe these symptoms, possibly because of the large dilation of the tubules, which precluded urinary obstruction (PINTO et al., 2004).

We did not observe any symptoms resulting from infection with *P. bragai*. Such symptoms may be related to the parasite load of the definitive host. Pinto et al. (2004) stated that high parasite loads can result in the development of certain symptomatology and cited the symptoms reported by Arnizaut et al. (1992). Nevertheless, the severity of the microscopic lesions is not related with the parasite load, which demonstrates the low pathogenicity of *P. bragai* (PINTO et al., 2004). Likewise, Menezes et al. (2001) stated that despite the large size of the adult parasite, the location and average intensity of infection, these factors do not result in serious macroscopic or microscopic lesions.




Figure 2. Pseudostratified epithelium of the collecting tube wall of a kidney infected with *P. bragai*. **2a.** Histological section of a kidney from *G. gallus* naturally infected with *P. bragai*, showing the pseudostratified epithelium with nuclei of different heights (oval detail). **2b** and **2c.** SEM micrographs of histological sections, showing pseudostratified epithelium with nuclei (arrows) in different positions of the collecting tubule wall after experimental infection of *P. bragai* (P) with eggs (E) in *C. livia*. Scale bars = 40 μ m and 30 μ m, respectively.

However, even though very heavy infections were observed, we found symptoms that could be ascribed to the presence of *P. bragai*. Therefore, factors other than the parasite load should be considered, such as the conditions of the host organism, the genetic order or general order, nutritional state and existing pathologies (REY, 2008).

The findings of the macroscopic analysis in the present study corroborate those of Santos (1934), who, by external examination, observed that some kidneys of *C. livia* and *G. gallus* were slightly enlarged. The same finding was reported by Barretto & Mies Filho (1942) in *M. gallopavo*, by Portugal et al. (1972) in *C. livia*, by Arnizaut et al. (1992) in *C. inornata wetmorei*, and by Brandolini (2000) in *C. livia*. However, this finding was not reported by Menezes et al. (2001) in *N. meleagris*, by Pinto et al. (2004) in *C. talpacoti*, or by Brener et al. (2006) in *M. gallopavo*. Barretto & Mies Filho (1942) also observed accentuated atrophy of one of the kidneys, although this was not found in the present study.

In the macroscopic examination of the kidney sections from infected birds, we observed the presence of adult parasites in the collecting tubules, as evidenced by their dark brown color, due to the large number of eggs inside their uteruses. High infection rates can cause obstruction and hypertrophy of the tubules, as observed in this study and by other authors (BARRETTO & MIES FILHO, 1942; BRANDOLINI, 2000; BRENER et al., 2006; MENEZES et al., 2001; PINTO et al., 2004; SANTOS, 1934).

Based on the microscopic examination of kidney tissue sections, our observation of dilation of the collecting tubules of the medullar region due to the presence of *P. bragai* is in line with the findings of Santos (1934), Barretto & Mies Filho (1942), Kumar et al. (2009) and Unwin et al. (2013), who analyzed *Paradisaea rubra* Daudin, 1800 (Passeriformes) and *Z. graysoni* (Columbiformes).

About the classification of the epithelium of the collecting tubule wall in the presence of *P. bragai*, there are some divergences in the literature, such as: Santos (1934), the collecting tubules had thick walls and multistratified epithelium compressing adjacent tubules. The expression "multistratified epithelium" was also used by Ross et al. (1993) to classify the epidermis, one of the layers of the skin. This term designates a lining that has various layers of flattened and juxtaposed cells.

The epithelium of the collecting tubule wall of uninfected *C. livia* is classified as simple cuboidal, but its appearance changes when infected, as described here, from simple cuboidal to pseudostratified and prismatic, as seen in some tubules, while in others we observed flattening of the tubule wall cells. According to Junqueira & Carneiro (1995), pseudostratified is a term employed to classify the epithelium when, although there is only one layer, it appears to have multiple layers due to the location of nuclei at different heights.

The appearance of various cell layers could explain the classification "multistratified epithelium" adopted by Santos (1934). However, the classification adopted by Santos (1934) could also be mistaken, since metaplasia could have occurred in the epithelium of the collecting tubules due to infection with *P. bragai*, a supposition supported by the present study. The infection with *P. bragai* could have caused the nuclei to occupy different positions, thus making 'pseudostratified' rather than 'multistratified' the correct description. Therefore, Santos (1934)

results may not have been multiple layers of cells, but rather a shift in the positions of some nuclei and elongation of the cells, as we found in this study.

Flattened cells of the collecting tubule wall of experimentally infected *G. gallus* were also observed by Pinto et al. (2004) and Gomes et al. (2005), while Kumar et al. (2009) found atrophy of the epithelial lining.

Arnizaut et al. (1992) observed interstitial infiltrate of inflammatory cells inside the renal tubules, composed of heterophils and eosinophils, feature not observed in this study. The occurrence of inflammation near the collecting tubules as a result of infection with *P. bragai* observed in this study agrees with the findings of Menezes et al. (2001), who noted discrete inflammation with the presence of heterophils around the tubules in *N. meleagris* parasitized by *P. bragai*, and with those of Silva et al. (2005), who observed chronic interstitial nephritis, mainly heterophilic in nature. Unwin et al. (2013) also observed interstitial nephritis, while Gomes et al. (2005) found an inflammatory reaction with granulocytes, and Brener et al. (2006) observed a discrete heterophilic infiltrate between mononucleated cells.

Conclusions

Infection with *P. bragai* can cause dilation of the renal lobes of *C. livia*. The presence of the parasite caused substantial dilation of the kidney collecting tubules of the birds infected naturally and experimentally.

The occurrence of lymphoplasmacytic infiltration was observed only in natural infections.

The presence of *P. bragai* led to metaplasia of the epithelial lining of the kidney collecting tubules in experimentally infected *G. gallus*.

Acknowledgements

The authors gratefully acknowledge CAPES (Brazil's Federal Agency for the Support and Improvement of Higher Education) for its financial support, and the staff of the Otto Wucherer Helminth Biology Laboratory of the Carlos Chagas Filho Biophysics Institute, Federal University of Rio de Janeiro for their assistance with the photomicrographs.

References

- Arnizaut AB, Hayes L, Olsen GH, Torres JS, Ruiz C, Pérez-Rivera R. An epizootic of *Tanaisia bragai* in a captive population of Puerto Rican plain pigeon (*Columba inornata wetmorei*). *Ann N Y Acad Sci* 1992; 653(1): 202-205. <http://dx.doi.org/10.1111/j.1749-6632.1992.tb19647.x>. PMID:1626872
- Atkinson CT, Thomas NJ, Hunter DB. *Parasitic diseases of wild birds*. Blackell Publishing; 2008. <http://dx.doi.org/10.1002/9780813804620>.
- Barretto JF, Mies Filho AM. *Primeiras observações sobre a presença de "Tamerlanea bragai" (Prof. Violantino Santos, 1934) nos rins de Meleagris gallopavo domestica*. Rio de Janeiro: Departamento Nacional de Produção

- Animal, Serviço de Informação Agrícola, Ministério da Agricultura, Instituto de Biologia Animal; 1942. p. 3-6.
- Brandolini SVPB, Amato SB, Pereira AA. Relacionamento de *Tanaisia bragai* (Digenea, Eucotylidae) e seu hospedeiro intermediário, *Subulina octona* (Gastropoda, Subulinidae) sob condições experimentais. *Parasitol. dia* 1997; 21(3-4): 109-113.
- Brandolini SVPB, Amato SB. Desenvolvimento larval de *Paratanaisia bragai* (Santos) (Digenea, Eucotylidae) sob condições experimentais. *Rev Bras Zool* 2006; 23(4): 1097-1100. <http://dx.doi.org/10.1590/S0101-81752006000400017>.
- Brandolini SVPB. *Biologia de Tanaisia (Paratanaisia) bragai (Santos, 1934) (Digenea, Eucotylidae)* [Tese]. Rio de Janeiro: Universidade Federal Rural do Rio de Janeiro; 2000.
- Brener B, Tortelly R, Menezes RC, Muniz-Pereira LC, Pinto RM. Prevalence and pathology of the nematode *Heterakis gallinarum*, the trematode *Paratanaisia bragai*, and the protozoan *Histomonas meleagridis* in the turkey, *Meleagris gallopavo*. *Mem Inst Oswaldo Cruz* 2006; 101(6): 677-681. <http://dx.doi.org/10.1590/S0074-02762006000600017>. PMID:17072483
- De Carli GA. *Diagnóstico laboratorial das parasitoses humana: métodos e técnicas*. Rio de Janeiro: MEDSI Editora Médica e Científica; 1994.
- Fernandes MC. *Métodos escolhidos de técnicas microscópicas*. 2. ed. Rio de Janeiro: Imprensa Nacional; 1949.
- Gomes DC, Menezes RC, Tortelly R, Pinto RM. Pathology and first occurrence of the kidney trematode *Paratanaisia bragai* (Santos, 1934) Freitas, 1959 (Digenea: Eucotylidae) in *Phasianus colchicus* L., 1758, from Brazil. *Mem Inst Oswaldo Cruz* 2005; 100(3): 285-288. <http://dx.doi.org/10.1590/S0074-02762005000300013>. PMID:16113870
- Humason GL. *Animal tissue techniques*. 4th ed. San Francisco: W.H. Freeman; 1979.
- Junqueira LC, Carneiro J. *Histologia básica*. 8. ed. Rio de Janeiro: Guanabara Koogan; 1995.
- Keller GG, Araújo JLB. Ciclo evolutivo de *Paratanaisia bragai* (Santos, 1934) (Trematoda, Eucotylidae) como novo hospedeiro intermediário no Brasil: *Leptinaria unilamellata* (D'Orbigny, 1835) (Gastropoda, Pulmonata, Subulinidae) em condições de laboratório. *Rev Bras Parasitol Vet* 1992; 1(2): 89-92.
- Kumar BM, Taibur R, Sushanta G, Saidul I. On the incidence and pathology of *Paratanaisia bragai* dos Santos, 1934 (Freitas, 1959) infection in domestic pigeon (*Columba livia*). *J Vet Parasitol* 2009; 23(2): 159-161.
- Luna LG. *Manual of histologic staining methods of the armed forces institute of pathology*. New York: McGraw-Hill Book Company; 1968.
- Maldonado JF. The life cycle of *Tamerlania bragai*, Santos, 1934 (Eucotylidae), a kidney fluke of domestic pigeons. *J Parasitol* 1945; 31(5): 306-314. <http://dx.doi.org/10.2307/3273085>.
- Menezes RC, Mattos DG Jr, Tortelly R, Muniz-Pereira LC, Pinto RM, Gomes DC. Trematodes of free range reared guinea fowls (*Numida meleagris* Linnaeus, 1758) in the state of Rio de Janeiro, Brazil: morphology and pathology. *Avian Pathol* 2001; 30(3): 209-214. <http://dx.doi.org/10.1080/03079450124448>. PMID:19184902
- Pinto RM, Menezes RC, Tortelly R. Systematic and pathology study of *Paratanaisia bragai* (Santos, 1934) Freitas, 1959 (Digenea, Eucotylidae) infestation in ruddy ground dove *Columbina talpacoti* (Temminck, 1811). *Arq Bras Med Vet Zootec* 2004; 56(4): 472-479. <http://dx.doi.org/10.1590/S0102-09352004000400008>.
- Portugal MASC, Oliveira GF, Fenerich FL, Cappelaro CEMPM, Chiarelli V. Ocorrência de *Paratanaisia bragai* (Santos, 1934) Freitas, 1959 (Trematoda Eucotylidae), em pomba doméstica (*Columbia livia domestica*). *Arq Inst Biol* 1972; 39(3): 189-194.
- Rey L. *Parasitologia*. Rio de Janeiro: Guanabara Koogan; 2008.
- Ross MH, Reith EJ, Romrell LJ. *Histologia, texto e atlas*. 2. ed. São Paulo: Panamericana; 1993.
- Santos V. Monostomose renal de aves doméstica. *Rev Dep Nac Prod Animal* 1934; 1: 203-215.
- Silva MEM, Mattos-Júnior DG, Tortelly R, Menezes RC. Lesões causadas por alguns helmintos em galinha-d'angola (*Numida meleagris*, L.) procedentes de estado do Rio de Janeiro. *R Bras Ci Vet* 2005; 12(1-3): 118-123.
- Unwin S, Chantrey J, Chatterton J, Aldhoun JA, Littlewood DTJ. Renal trematode infection due to *Paratanaisia bragai* in zoo housed Columbiformes and a red bird-of-paradise (*Paradisaea rubra*). *Int J Parasitol Parasites Wildl* 2013; 2: 32-41. <http://dx.doi.org/10.1016/j.ijppaw.2012.11.001>. PMID:24533313